



## STUDIES ON OCULAR *SARCOCYSTIS* IN BUFFALOES IN ASSIUT GOVERNORATE

M. I. Arafa\* ; M.M.Monib\*\* ; A.K.Dyab\*\* and S.KH.Abdel-Ghaffar\*\*\*

\* Animal Health Research Institute, Assiut Lab., \*\*Parasitology Dept. Faculty of Med.  
and \*\*\* Pathology Dept. Faculty of Vet. Med. Assiut University

---

### ABSTRACT :

A total of 150 buffalo's ocular muscle samples were examined for the presence of sarcosporidians in Assiut Governorate. These samples included 80 males less than 2 years old and 70 females more than 5 years old. *Sarcocystis* spp. were detected in 55 (36.66%) of examined animals. The incidence of infection in males was 15.0% and in females was 61.42%. Two species of *Sarcocystis* were detected in the present work: *S.fusififormis* was detected in 9.33% of examined animals, where in males it was 1.25% and in females was 18.57%. *S.levinei* was detected in 34.66% of examined animals, in males it was 15.0% and in females was 57.14%. Mixed infection with the two species was detected in 11 (7.33%) of examined animals. The morphological characters and the ultrastructure of each species were described. The present data showed that ocular muscles are a preferable site for *Sarcocystis* especially *S.levinei*. It is ,therefor recommended that *Sarcocystis* cysts showed be looked for in ocular muscles of humans complaining of ocular muscle disease.

---

### INTRODUCTION:

Sarcosporidia are protozoal parasites found in wide variety of animals and man, where more than 50 species are detected in mammals and birds (Gracey and Collins, 1992). *Sarcocystis* has an obligatory prey predator (2 hosts) life cycle, asexual stages develop in intermediate host (predator) which is herbivorous and sexual stages develop in definitive host (prey) which is carnivorous, predator may act as a prey at the same time (Levine, 1986). *Sarcocystis* is found mainly in striated muscles (Skeletal

and cardiac muscles) where it causes myositis, degenerative changes and atrophy of muscles around the cysts (Smith *et al.*,1972; Yassein, 1984 and Sharma and Mazaheri,1992). Three species of *Sarcocystis* were detected in buffaloes *S.fusififormis*, *S.levinei* and *S.buffalonis*, each one has a distinct cyst wall structure. *S.fusififormis* and *S.buffalonis* form macroscopic sarcocysts and are transmitted to buffaloes via faeces of cats, while *S.levinei* forms microscopic sarcocysts and is transmitted to buffaloes via faeces of dogs (Dissanike & Kan 1978 and Huang *et al.*, 1997). Generally,

macroscopic species of *Sarcocystis* are non pathogenic, whereas some microscopic species may cause anemia, weight loss, abortion and death in their hosts (Dubey *et al.*, 1989).

In Egypt two species (*S.fusiformis* and *S.levinei*) were detected in buffaloes in different localities by several authors (El.Afifi *et al.*, 1962, Abdel-Rahman, 1975, Ali 1985, Hassanien 1992, El-Saieh, 1998 and Mandour *et al.*, 1998). The ultra-structure of *S.fusiformis* was studied by Abdel-Ghaffar *et al.* 1978 and Mandour *et al.* 1998. Ocular musculature appears to be a preferred site for development of *Sarcocystis* in different intermediate hosts (Juyal *et al.*, 1982). Therefore, the aim of the present work was to determine the incidence of different species of *Sarcocystis* in ocular muscles of buffaloes in Assiut Governorate, as well as identify the species and describe the morphological characters of each species and their ultrastructure.

## **MATERIALS AND METHODS:**

**Collection of samples:** Ocular muscle samples were collected from 150 buffaloes (80 males under 2 years and 70 females more than 5 years) from different localities of Assiut Governorate.

### **Parasitological examination:**

- Each sample was examined macroscopically for detection of macroscopic cysts.
- Microscopical examination was also done by compressing of small pieces of muscle between two slides (Mowafy, 1993).
- For detection of liberated trophozoites, homogenization of muscle samples was done with physiological salt solution (Ali, 1985).

### Histomorphological examination:

- Some muscular specimens from positive cases and macroscopic cysts were fixed in 10% neutral buffered formalin, these samples were dehydrated in alcohols and stained with haematoxylin and eosin then examined microscopically (Bancroft and Stevens, 1993).
- Other selected specimens were fixed in 2.5% buffered glutaraldehyde and processed for electron microscopy (Johannessen, 1978).
- Semithin sections were made and examined by light microscope.
- Ultrathin sections were then prepared, stained with uranyl acetate lead citrate stain and examined by JEOL-EM 100 CXII electron microscope.

*Sarcocystis*. Incidence of infection with *Sarcocystis* in males was 15% and in females was 61.42%. Two species of *Sarcocystis* were detected in the present work, the first specie was *S.levinei* which was detected in 52 (34.66%) of examined animals. Their incidence in males was 15% and in females was 57.14%. The second specie was *S.fusiformis* which was detected in 14 (9.33%) of examined animals. Their incidence in males was 1.25% and in females was 18.57%. Mixed infection of *Sarcocystis* species was detected in 11(7.33%) of examined animals. The infection rate in animals more than 5 years was 61.42% while in animals less than 2 years was 15% (Table 1).

### RESULTS:

Out of 150 ocular muscle samples of buffaloes, 55(36.66%) were infected with

Table (1): Incidence of *S.levinei* and *S.fusiformis* in ocular muscles of buffaloes.

	Examined animals	Infected animals		Single <i>S.levinei</i>		Single <i>S.fusiformis</i>		Mixed infection		Total			
		No.	%	No.	%	No.	%	No.	%	<i>S.levinei</i>		<i>S.fusiformis</i>	
										No.	%	No.	%
Males less than 2 years	80	12	15	11	13.75	-	-	1	1.25	12	15	1	1.25
Females more than 5 years	70	43	61.42	30	42.85	3	4.28	10	14.28	40	57.14	13	18.57
Total	150	55	36.66	41	27.33	3	2	11	7.33	52	34.66	14	9.33

### Morphological description:

**1-*Sarcocystis fusiformis*:** It appears grossly as broad, white cyst not embeded deeply between the ocular muscle fibers, measuring 3.0-15.0 mm long (mean 9.0 mm) and 1-4 mm wide (mean 2.5 mm) (PlateI, Fig.1). Histopathological examination revealed that the cyst wall is relatively thin measuring 2-4 μ and provided with cyst wall-processes (cytophaneres) which are cleared by semithin section as a highly branched

villar protrusions like a cauliflower. These villar protrusions are attached to each other giving the wall spongy appearance. Septa arise from the inner surface of cyst wall dividing each cyst into chambers containing groups of crescentic trophozoites. These trophozoites measure 12-15.4μ x 2.5-4.5μ (13.5x3.8μ). Between the inner side of the wall and these chambers there are a number of metrocytes of variable size (Plate I Fig. 2, 3). Ultrastructure examination of the cyst

has shown that the parasitophorous vacuolar membrane (PVM) of the villar protrusions is wavy and possesses small papillary projections. Their ground substance contain numerous microfilaments (MF) and electron dense granules (Ed). Longitudinal section of bradyzoites shows numerous micronemes (Mn) at the apical end. The middle part of the bradyzoite contains polysaccharide granules (Ps), and refractile bodies (Rb) of variable size while the nucleus is located at the posterior end (Plate I 4, 5).

**2-*Sarcocystis levinei*:** It was detected microscopically. It appears as a small spindle shaped cyst measuring 0.40-0.86 mm long (0.70mm) and 0.10-0.17mm wide (0.14mm). The cyst wall is thick measuring 4-7 $\mu$  and appeared finely striated by light microscope. Examination of semithin section cleared that these striations are finger-like projections located on well distinct basement membrane. They are not branched and unequal in length. Their distal end is dome-shaped while their anterior end is tapering toward the host cell. No septa were detected in examined cysts and their trophozoites are collected in large number in groups. The trophozoites measuring 9.5-11.8x 2-3.5 $\mu$  (10.8x3 $\mu$ ). Overcrowding of trophozoites obscure any morphological details inside the cyst except the presence of few number of small rounded metrocytes, adhering to the inner side of the wall (Plate II Fig. 1, 2). Ultrastructure of the cyst has shown that the surface of villar protrusions is smooth and not papillated while their ground substance is finely granulated and lacks microfilaments. The bradyzoite has the same morphological characters of

*S.fusiformis* in addition to presence of ductules of rhoptry (Dr) at the anterior part. Longitudinal section of metrocytes appears as peculiar cell, where it is characterized by thick and infolding pellicle. It is provided with two refractile bodies (Rb) one is small and anterior to nucleus while the second is so large and posterior to the nucleus. These bodies are osmiphilic, electron dense and homogenous. Nucleus is located at the middle of metrocyte and it has a small round nucleolus. Septa appear as a very thin double membrane behind the metrocyte (Plate II 3, 4).

## DISCUSSION:

Ocular muscles play an important role in dissemination of *Sarcocystis* infection. Because eye and its surrounds musculature are considered as unedible parts for human consumption. So these parts are thrown away by the butchers and eaten by carnivorous animals which are the definitive hosts of *Sarcocystis*. In the present work *Sarcocystis* infection was detected in 36.66% of examined samples, the incidence of both *S.levinei* and *S.fusiformis* was 34.66% and 9.33% respectively. This result is considered so high than that detected by Mansour (1994) who detected *S.fusiformis* in 0.48% of examined buffaloes. This difference may be attributed to the method of diagnosis, which depended only on macroscopical examination of buffaloes in abattoirs.

The prevalence of infection of both species of *Sarcocystis* in the present work was high in females (61.42%) than males (15.0%). This result agrees with Ali (1985) and El-Saieh (1998). The difference of infection rate between males and females is

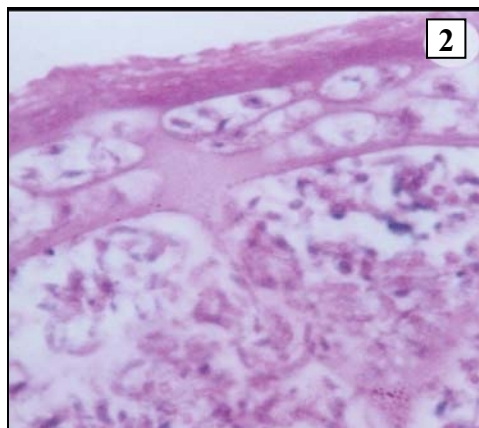
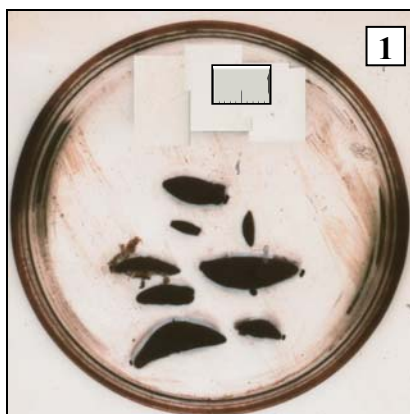
attributed to that the prevalence of *Sarcocystis* infection which is mainly high in aged animals.

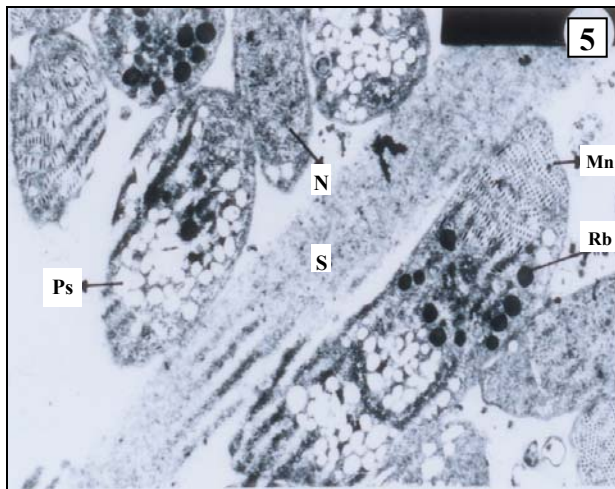
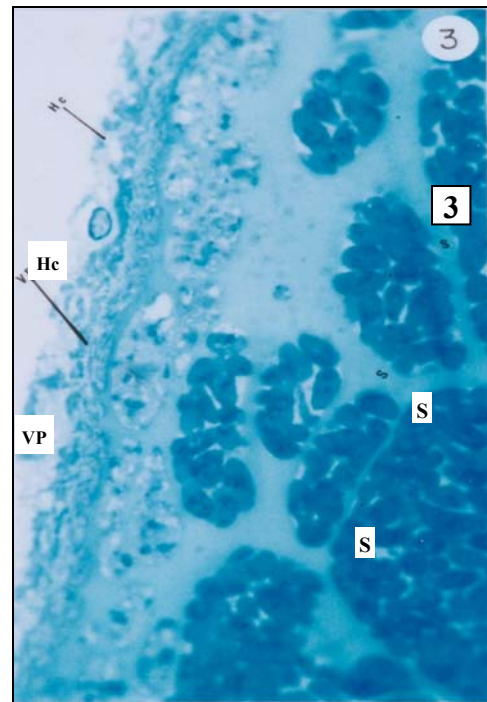
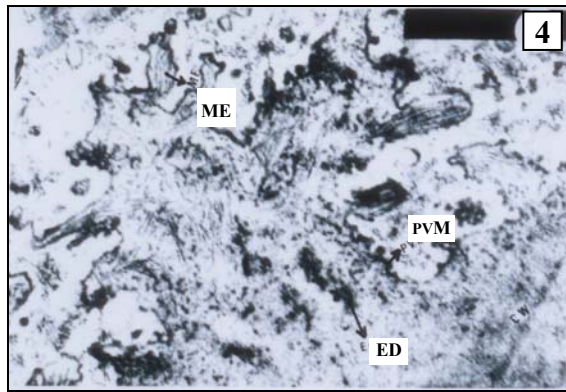
Concerning the morphological studies of *Sarcocystis*, the results of the present work agrees with the opinion of Mandour (1974) who mentioned that: the cyst wall and morphological characters of villar protrusions are considered the main criteria to differentiation between species of *Sarcocystis*. The morphological characters and ultrastructure studies of cyst wall and bradyzoites of *S.fusififormis* in the present work agrees with the description of the previous authors as Mandour (1974) and Abdel-Ghaffar *et al.* (1978), but it differs from that described by Mandour *et al.*, (1998) which was known as *S.fusififormis aegyptii*. This difference may be attributed to the age of the cyst.

The present morphological study of *S.levinei* is considered the first report in

Egypt, especially the description of the cyst wall and their ultrastructure. The villar protrusions of the cyst wall of *S.levinei* are characteristic and easily differentiate it from those of the cyst wall of *S.fusififormis*. The morphological characters of *S.levinei* in the present work agrees with the description of Dissanaik & Kan (1978). Although *Sarcocystis* species found in livestock are considered host specific, the manner of arrangement of the villar protrusions in *S.levinei* is closely similar to that of *S.cruzi* of cattle described by Claveria *et al.*, 2001. The large number of villar protrusions on the surface of the cyst of *S.levinei* are important for nutritional requirement. This large number increase the surface area which lead to enhance the nutritional absorption.

Plate (I): Morphological characters and ultrastructure of *Sarcocystis fusiformis*





1-Grossly visible sarcocysts in ocular muscle.

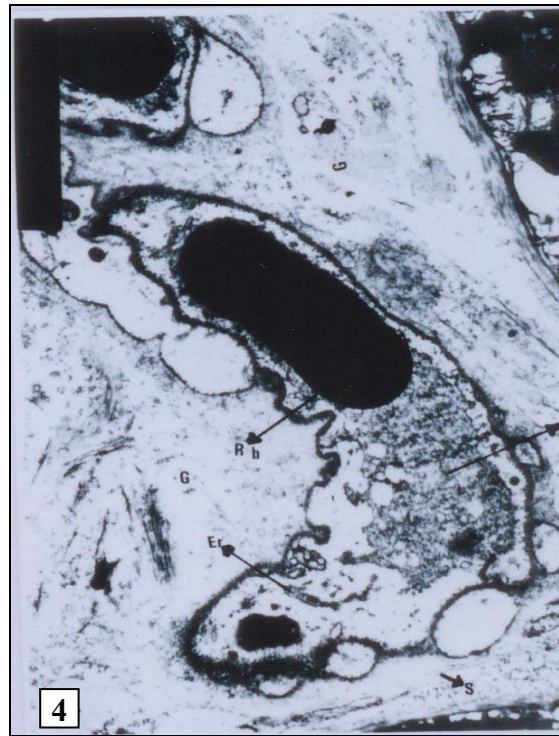
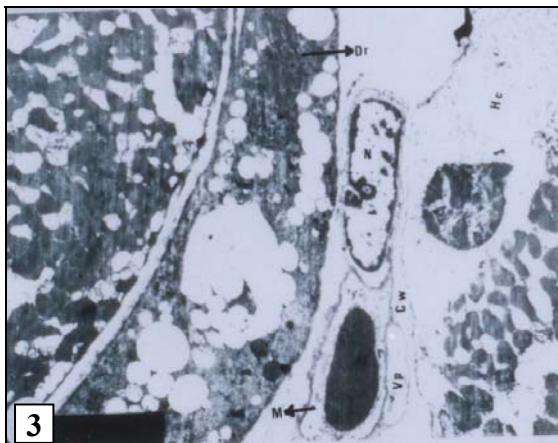
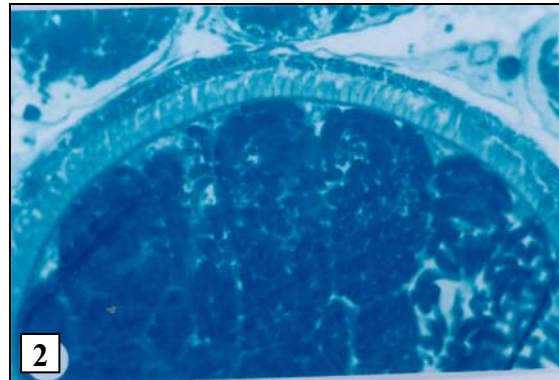
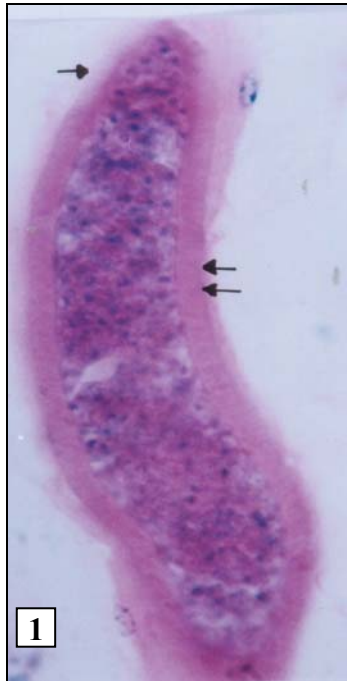
2-Light micrograph of sarcocyst showing septa, metrocytes and aggrigation of bradyzoites (H&E X1000).

3-Semithin section of sarcocyst. Note host cell (Hc), villar protrusions (Vp) and septa (S). Toulidine blue stain X1000.

4-Transmission electron micrograph of villar protrusion. Note microfilaments (Mf), Electron dense granules (Ed), wavy parasitophorous vacular membrane (PVM) and cyst wall (Cw) X10000.

5-Transmission electron micrograph of bradyzoites. Note septa (s) micronemes (Mn) at the apical end, polysaccharide granules (Ps), refractile bodies (Rb) and nucleus (N) at the posterior end X5000

**Plate (II): Morphological characters and ultrastructure of *Sarcocystis levinei*.**



- 1-Light micrograph of sarcocyst in ocular muscle. Note fine striation cyst wall (opposing arrows) H&E X1000.
- 2-Semithin section of sarcocyst. Note finger like projection of the villar protrusions. Toulidine blue stain X 1000.
- 3-Transmission electron micrograph of the same cyst. Note ductule of rhoptry (Dr) at the anterior end of merozoite, section of merozoite (M) and their nucleus (N), section of the villar protrusion (Vp) and host cell (Hc) X2700.
- 4-Transmission electron micrograph of merozoite. Note refractile body (Rb), nucleus (N), endoplasmic reticulum (Er) ground substance (G) and very thin septa (S). X4000.

The refractile bodies in the metrocytes of *S.levinei* in the present work are so large. These are similar to that of *Eimeria ninakolyakimovae* sporozoite of goat described by Scholtyseck (1979). He added that, the refractile bodies are one of the most prominent fine structure of subphylum Apicomplexa.

According to the previous results we could concluded that:

Ocular muscles are considered a preferable site for *Sarcocystis* especially *S.levinei*. It is, therefor recommended that *Sarcocystis* cysts should be looked for in ocular muscles of humans whenever clinical manifestations devotes muscle disease. Ultrastructure studies of the cyst wall could be used as one of important method to identify different species of *Sarcocystis*.

## REFERENCES:

- 1-Abdel-Ghaffar, F.; Hilali, M. and Scholtysek, E. (1978): Ultrastructural study of *Sarcocystis fusiformis* (Railliet, 1997) infecting the Indian water buffalo (*Bubalus bubalis*) of Egypt. Tropenmed. Parasit., 29:289-294.
- 2-Abdel-Rahman, M.A. (1975): Studies on protozoa of ruminants in Assiut Governorate. Ph. D. Thesis, Prarasit. Fac. of Vet. Med. Assiut Univ.
- 3-Ali, G.A.T. (1985): Studies on *Sarcocystis* of animals in Assiut Governorate. M.V.Sc. Thesis, Fac. Of Vet. Med. Assiut Univ.
- 4-Bancroft, J.D. and Stevens, A. (1993): Theory and Practic of Histologic Techniques, 3<sup>rd</sup> Ed. Long Man Group Limited.
- 5-Claveria, F.G; San-pedro, L.R.; Cruz-Flores, M.J.; Nagasawa, H.; Suzuki, N. and De Le Pana, C. (2001): Ultra structural studies of *Sarcocystis cruzi* (Hasselmann, 1926) Wenyon, 1926 infection in cattle (*Bos taurus*): Philippine cases. Parasitol. 8 (3) 251-254.
- 6-Dissanike, A.S. and Kan, S.P. (1978): Studies on *Sarcocystis* in Malaysia. 1- *Sarcocystis levinei* n. sp. from water buffalo *Bubalus bubalis*. z. Parasitenkd. 55:127-138
- 7-Dubey, J.P., Speer, C.A. and Fayer, R. (1989): Sarcocystosis of animals and man. CRC.Press Inc. Boca Raton. Florida 215 p.
- 8-El- Afifi, A.; Abdou, A.H. and El-Sawah, H.M.(1962): Incidence of sarocosporidiosis in the United Arab Republic. Vet. Med. J., 8 (9): 195-201.
- 9-El-Saieh, A.F.; (1998): Incidence of *Toxoplasma* and *Sarcosporidia* in Qena Governorate. Ph. D. Thesis, Fac. of Vet. Med. Assiut Univ.
- 10-Gracey, J.F. and Collins, D.S. (1992): Meat Hygiene, 9<sup>th</sup> Ed. EIBS, Bailliers Tindall, London.
- 11-Hassanien, F.S. (1992): Incidence of protozoa among slaughtered animals in Kalyobia Governorate with special reference to toxoplasmosis. Ph. D. Thesis, Fac. Vet. Med. Zagazig Univ.
- 12-Huong, L. T.T., Dubey, J.P., Tapio Nikkila and Arvid Ugglä. (1997): *Sarcocystis Buffalonis* n. sp. (Protozoa : Sarcocystidae) from water buffalo (*Bubalus bubalis*) in Vietnam. J. Parasit. 83:(3)471-474.
- 13-Johannessen J. (1978): Instruction and Techniques in: Electron Microscopy in Human medicine. Vol. 1. Mcgrawhill international book company.



- 14-Juyal, P.D.; Sahai, B.N.; Srivastara, P.S.; Sinha, S.R. (1982): Heavy sarcocystosis in the ocular musculature of cattle and buffaloes. *Vet. Res. Com. Nov.*, 5(4) :337-342.
- 15-Levine, N.D. (1986): The taxonomy of *Sarcocystis* (Protozoa, Apicomplexa) species. *J. Parasitol.* 72:372-382.
- 16-Mandour, A.M. (1974): Fine structure of *Sarcocystis blanchardi* (Doflein, 1901) from Egyptian buffalo. *Assiut Vet. Med. J.*, 1 (1, 2) 101-105.
- 17-Mandour, A.M., Sayed, F.G., Hamza, A.I. Abdel-Rahman, S.M. and El-Nazer, M. (1998): *Sarcocystis fusiformis aegyptii* n.sp. in the oesophaegi of the Egyptian buffalo (*Bubalus bubalis*). *Egypt. J. Med. Sci.* 19: (2) 483-495.
- 18-Mansour, N.K. (1994): Incidence of some zoonotic agents and tuberculosis in slaughtered buffaloes (*Bubalus bubalis*). *Vet. Med. J., Giza*: 43 (2) 231-239.
- 19-Mowafy, N.M. (1993): Sarcosporidiosis in Rodents. Ph. D. Thesis Fac. of Med. Minia Univ.
- 20-Scholtzseck, E. (1979): Fine structure of parasitic protozoa. Springer-varlag Berlin. Heidenlberg.
- 21-Sharma, R.N and Mazaheri, Y. (1992) Eosinophilic myositis in a goat. *Vet. Med. Rec.* 130, 16 : 359 .
- 22-Smith, H.A.,; Jones, T.C. and Hunt, R.D. (1972): *Veterinary pathology*, 4<sup>th</sup> Ed. Lea. and Febiger, Philadelphia, P.A.
- 23-Yassein, M.A.M. (1984): Muscular parasites in slaughtered camels. Ph. D. Thesis, Fac. of Vet. Med. Cairo Univ.

دراسات عن الساركوسستس العيني في الجاموس في محافظة أسيوط  
محسن إبراهيم عرفه\*، محمد الصلاحي محمد منيب\*\*، أحمد كمال دياب\*\*،  
سارى خليل عبد الغفار\*\*\*

\*معهد بحوث صحة الحيوان - معمل بيطرى أسيوط، \*\*قسم الطفيليات - كلية الطب،  
\*\*\* قسم الباثولوجى - كلية الطب البيطرى - جامعة أسيوط

تم فحص عدد ١٥٠ عينة من عضلات العيون في الجاموس لعمل دراسة طفيلية عن تواجد الساركوسستس في محافظة أسيوط. واشتملت تلك العينات على ٨٠ عينة من الذكور أقل من عامين و ٧٠ من الإناث أكبر من خمس سنوات. وبلغت نسبة الإصابة الساركوسستس ٣٦,٣٣% حيث تم اكتشافها في ٥٥ حيوان.

بلغت نسبة الإصابة في الذكور ١٥% وفي الإناث ٦١,٤٢%. وتم تصنيف الساركوسستس إلى نوعين الأول: ساركوسستس فيوزفورمس حيث كانت نسبة الإصابة به ٩,٣٣% فقد بلغت نسبة الإصابة في الذكور ١,٢٥% وفي الإناث ١٨,٥٧%. والنوع الثانى هو ساركوسستس ليفينى، وقد كانت نسبة الإصابة به ٣٤,٦٦% حيث كانت نسبة الإصابة في الذكور ١٥% وفي الإناث ٥٧,١٤%. وقد كانت نسبة العدوى المشتركة من النوعين ٧,٣٣%. وقد تم وصف الشكل المورفولوجى والتركيب الدقيق لكل نوع بواسطة الميكروسكوب الإلكتروني.

وقد أثبتت التجارب الحالية أن عضلات العين تعتبر مكانا مفضلا لطفيل الساركوسستس وخاصة ساركوسستس ليفينى ولذلك يوصى الباحثون بفحص عضلات عيون الإنسان في حالة الشكوى من أعراض مرضية بها .