



ENTEROCOCCUS DURANS INFECTION IN CHICKS

Hebat-Allah Abd El-Halim Mohamed

Animal Health Research Institute, Assiut Provincial Laboratory

ABSTRACT:

90 samples from (liver, spleen and brain) of freshly dead and sick 4-7 days old balady chicks (with depression and mild nervous signs) were collected from different farms at Assiut Governorate. Also 120 dead in shell chicken embryos were collected from different hatcheries. *Enterococcus durans* was isolated at a rate of 66.6% from livers and spleens of chicks and at a rate of 27.7% from brains. The organism was isolated from dead in shell chicken embryos at a rate of 70.8% from livers and spleens and from brain at a rate of 20.8%. This indicates that the organism is transmitted through contaminated eggs from mothers or through contamination with faecal matter containing the organism. Experimental infection of healthy 1-day old balady chicks subcutaneously, intramuscularly and intraperitoneally with the isolated organism resulted in depression, some nervous signs and septicaemia in all chicks.

Mortality rate reached to 80%, 60% and 50% in chicks which infected intraperitoneally, intramuscularly and subcutaneously respectively. Gross lesions revealed congestion and enlargement of livers and spleens, enlargement of gallbladder, petechial haemorrhages in the brains, enteritis, Congestions and enlargement of kidneys with precipitation of uric acid in the ureters. Reisolation of the organism from experimentally infected chicks was succeeded. In vitro sensitivity test revealed that the gentamycin, ampicillin and naladixic acid were the most effective drugs.

INTRODUCTION:

Genus *Enterococcus* is composed of gram-positive, spherical bacteria which are nonmotile, nonspore-forming and facultative anaerobes. *Enterococcus* species (*Enterococcus* spp.) isolated from avian species and associated with disease includes: *Enterococcus faecalis* (*E. faecalis*), *E. faecium*, *E. durans*, *E. avium* and *E. hirae*. They are lancefield antigenic serogroup D streptococci.

Farrow *et al.*, (1983) stated that Streptococcosis included Streptococci in both lancefield antigenic serogroups C and D.

Collins *et al.*, (1984) cited that lancefield serogroup D Streptococci are commonly referred to as "fecal streps". It has been proposed that these Streptococci should more appropriately be placed in the genus *Enterococcus*.

Lewis and Zervos (1990) and Devriese *et al.*, (1991) reported that the application of new bacteriologic techniques especially DNA-DNA and DNA-RNA hybridization has led to reclassification of the lancefield group D Streptococci to the *Enterococcus* spp. . *Enterococcus* spp. in avian species is world wide

in distribution. They are ubiquitous in nature and commonly found in various poultry environment.

Bailey and Scott's (1994) come to that the conclusion the classification of these cocci has not been finalized but two groups are now assigned to a separate genus within the family Streptococcaceae. They are associated with diseases in poultry (chicken, turkey and duck) and other birds, they are Streptococci and Enterococci. Among the Enterococci those associated with disease are classified in lancefield's group D and include : *E. avium*, *E. faecium*, *E. durans*, *E. Faecalis*. Enterococcus organism is spherical, gram positive, non motile, ferment sugar usually to lactic acid. Common avian isolates can be differentiated by their ability to ferment mannitol and L.arabinose and by their growth on MacConkey's agar. In recent years, Devrise *et al.*, (1991) noticed that, torticollis or stargazing has been found in first-week chicks with encephalomalacia caused by some lancefield group D Streptococcus species, some of which are reported as part of the normal intestinal flora of young chickens.

Enterococcus spp. in poultry can result in two distinct clinical forms of disease, acute and subacute/chronic. In the acute form clinical signs are related to septicemia and include depression, lethargy, pale combs and wattles, ruffled feathers, diarrhea, mild head tremors and often, only dead birds are found. In the subacute/chronic form, depression, loss of body weight, lameness and head tremors may be observed. Clinically affected birds eventually die if not treated (Joan and McNamee 2002).

Cardona *et al.*; (1993) and Chamanza *et al.*; (1998) observed that Enterococcus *durans* causes encephalomalacia mainly in the medulla oblongata and cerebellum. The affected flocks had mortality over seven days, starting from the

fourth until the 10th day of age. Clinically the disease was associated with a wide range of features such as severe depression, Paralysis, leg tremors and increased mortality.

Egg transmission or fecal contamination of hatching eggs with Enterococci results in late embryo mortality and an increased number of chicks unable to "pip" or penetrate through the shell at hatch or at the time of hatching can adversely affect chicks early in life (Rudy 1991 and Al aboudi *et al.*, 1992).

Wages (2003) reported that *E. durans* is intestinal inhabitants of birds and mammals and its spread either directly through the egg or indirectly by the oral or respiratory routes and perhaps via skin wounds and causing disease in birds of any age but the severity is always greater in embryos and young chicks. Enteric infections or any condition compromising the intestinal villous epithelium and allowing penetration of resident enterococci can result in septicemia and/or bacterial endocarditis.

The present work is designed to cover the following points:

- Isolation and identification of Enterococcus. *durans* from baby chicks and dead in shell chicken embryos.
- Experimental infection of the isolated organism to 1-day old chicks by different routes.
- In vitro sensitivity test to determine the drugs of choice against the isolated organism.

MATERIALS AND METHOD:

Materials:

Samples:

A total of 90 samples (liver-spleen-brain) from freshly dead chicks and diseased chicks (depressed and had neurological signs) 4-7 days old and 120 dead in shell embryos, were

collected from different farms and hatcheries at Assiut Governorate.

Media used were:

MacConkey's agar, blood agar, nutrient agar, semisolid agar and sugar fermentation media.

Reagent, stain and solutions :

3% Hydrogen peroxide, Sodium Hippurate solution, Esculin broth with ferric citrate, 6.5% NaCl and ninhydrin reagent and Gram's Stain.

Experimental birds:

Forty, 1-day old balady chicks were used in this experiment. They were obtained from the faculty of Agriculture Assiut University poultry farm.

Antibiotic sensitivity discs used were:

Penicillin (10 IU), erythromycin (15 µg), oxytetracycline (30 µg), tetracycline (30 µg), gentamicin (10 µg) streptomycin (10µg), ampicillin (10 µg) naladixic acid (30 µg) and chlortetracycline (30 µg).

Methods:

Isolation:

Samples from liver, spleen and brain taken from diseased and freshly dead chicks and were cultured onto MacConkey's agar and blood agar medium and incubated at 37°C for 48 h. in 7% carbon dioxide. Tolerance test included growth in 6.5% sodium chloride and growth at 10°C and at 45°C were done to differentiate between *Enterococcus* spp. and *Streptococcus* spp.

Identification of the isolated organism:

The suspected colonies were examined for their morphology. Films from suspected colonies were stained by Gram's stain and to differentiate genus *Streptococcus* from genus *Enterococcus* biochemical reactions were done according to Connie and George (1995). Also to differentiate between *Enterococcus* species, biochemical tests were done according to Baily and Scott's (1994), Facklam and Teixeira (1998) and wages (2003).

Pathogenicity test :

Forty, 1 day-old healthy balady chicks were used and 5 birds from them were tested before experiment and proved to be free from *E. durans* and other birds were infected with *E. durans* and divided as follow :

1st group: Ten, 1-day old chicks inoculated subcutaneously with 0.1 ml of saline suspension prepared from blood agar culture in a concentrate equivalent to No. 4 Macfarland opacity tubes (according to Cardona *et al.*, 1993).

2nd group: Ten, 1-day old chicks inoculated intramuscular with 0.1 ml of Macfarland standard 4 suspension of *E. durans* in sterile saline (according to Cardona *et al.*, 1993).

3rd group: Ten, 1-day old chicks received intraperitoneally 0.1 ml of Macfarland standard 4 suspension of *E. durans* in sterile saline (according to Cardona *et al.*, 1993).

4th group : Five, 1-day old chick were left as control.

Reisolation of *E. durans* from experimental birds were done.

In vitro sensitivity test :

The determination of sensitivity of the isolated organism against different antibiotic discs was done.

RESULTS:

Postmortem examination of naturally infected chicks showed swollen, congested livers and spleens, enlarged kidneys and congestion of subcutaneous tissues.

Bacteriological examination revealed growth of colonies on MacConkey's and blood agars with no haemolysis and the colonies grew at 10°C and at 45°C also growth appeared in the media containing 6.5% NaCl. Gram's stain showed gram-Positive, spherical bacteria occurring singly, in pairs or short chains.

Biochemical reactions revealed that the isolated organism was catalase-negative and was positive for Esculin hydrolysis, it was negative for mannitol, L-arabinose, sorbitol and sucrose but it was lactose positive. The organism was not motile.

According to the cultural characters, Gram's stain and the biochemical reactions, the frequency of the isolated *E. durans* in chicks and embryonated chicken eggs is illustrated in table (1).

Pathogenicity test :

Chicks in groups 1, 2 and 3 which inoculated with *E. durans* isolate, showed depression as in (Fig. 1), signs of septicemia and congestion of all carcass (Fig. 2) and brain (Fig. 3), congestions and enlargement of liver with petechial haemorrhages and enlargement of gall bladder (Fig. 4), enteritis (Fig. 5). Before death birds showed incoordination and some nervous signs (Fig. 6). Some birds showed congestion of kidneys with precipitation of urates in the ureters (Fig. 7). The birds in 1st, 2nd and 3rd groups showed mortality within 3 days postinoculation. Mortality rate in 1st group was (50%) while in 2nd and 3rd groups were (60% and 80%) respectively.

There was no signs, lesions or death in any bird in group 4.

Reisolation of *E. durans* from liver, spleen and brain of experimentally infected chicks was successful.

In vitro sensitivity test :

The effect of the different antibiotics to the isolated *E. durans* is illustrated in table (2).

Table (1): Illustrates the percentage of isolated *E. durans* in chicks and dead in shell chicken embryos

Samples	Positive Samples of liver& spleen		Positive Samples of brain	
	No.	%	No.	%
1-Chicks	60/90	66.6	25/90	27.7
2-Dead in shell chicken embryos	85/120	70.8	25/120	20.8

Table (2): Shows the result of sensitivity test

Antibiotic discs	Sensitivity of <i>E. durans</i> isolates
Gentamycin	+++
Ampicillin	+++
Naladixic acid	+++
Chlorotetracycline	++
Tetracycline	++
Oxytetracycline	++




Fig. (1): Shows depression of experimentally infected chicks



Fig. (2): Shows congestion of all carcass

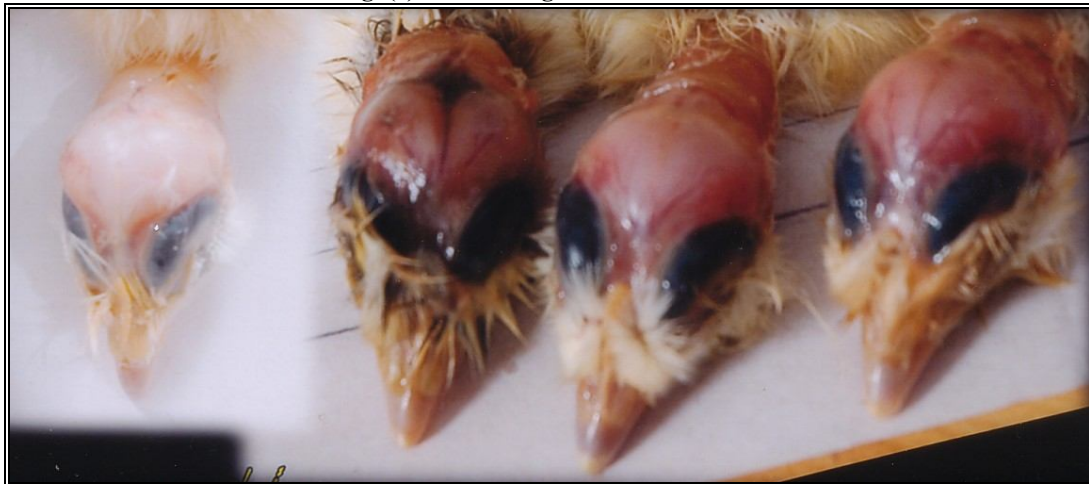

Fig. (3): Petechial haemorrhages in brains of experimentally infected chicks

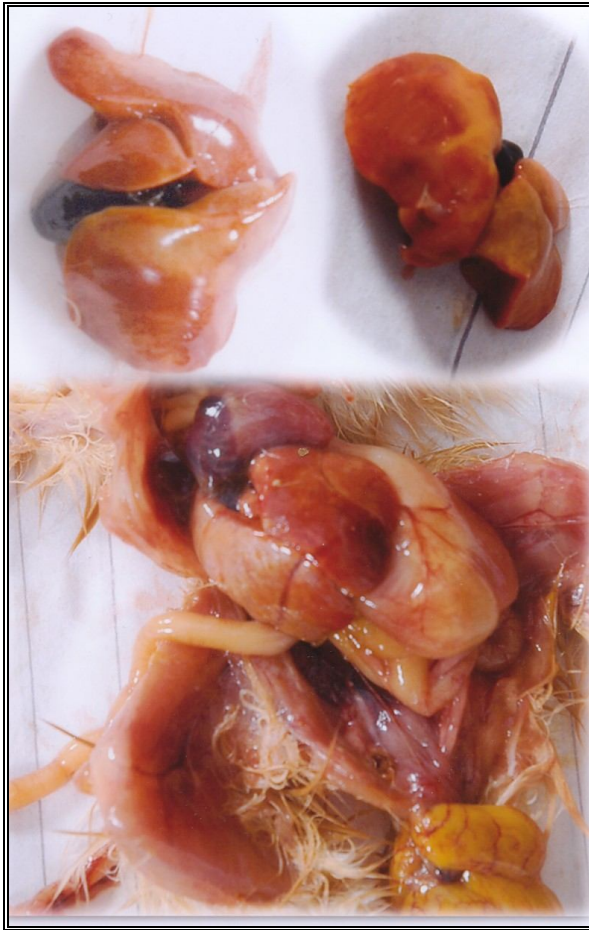


Fig. (4) : Enlargement of liver and gallbladder with petechial haemorrhages in the liver



Fig. (5): Shows enteritis



Fig. (6): Experimental infected chicks showed nervous signs

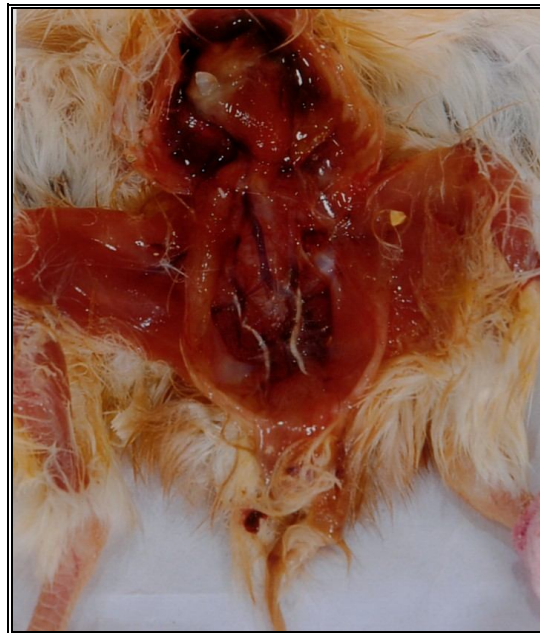

Fig. (7) : Congestion of kidneys with precipitation of urates in the ureters

DISCUSSION:

Enterococcus durans is a member of lancefield group D *Streptococcus* species.

This microorganism has been associated with brain infection in chicks. The outbreaks of *E. durans* encephalomalacia began when the chicks were 4 days old and the birds recovered by 10 days of age with no diet change or nutritional additives (Cardona *et al.*; 1993 Chamanza *et al.*; 1998 and Wages 2003).

In this study, bacteriological examination revealed that *E. durans* was recovered from livers and spleens of naturally infected chicks in percentage of (66.6%) and from brains at rate of (27.7%). This percent is less than that recorded by Cardona *et al.*; (1993) who could isolate *E. durans* from liver and spleens at a rate between 81% and 100% and from brain at rate between 30% and 45%.

In this study we could isolate *E. durans* from dead in shell chicken embryos at rate of (70.8%) from livers and spleens and (20.8%) from brains. This indicate that the organism is transmitted through eggs, so this result is in agreement with Alaboudi *et al.*; (1992).

Experimental infection of 1- day old chicks with the isolated organism showed depression, signs of septicemia and congestion of all carcass and brain. Congestions and enlargement of liver with petechial haemorrhages and enlargement of gall bladder and enteritis were recorded.

Before death, birds showed incoordination and some nervous signs. This result is the same with that observed in naturally infected chicks and reported by Cardona *et al.*; (1993), but we differ with them, in their experimental infection to chicks, the nervous signs were not observed although they reisolated the organism from brain of the inoculated chicks. But they noticed bacteremia and enlargement of liver and spleen.

We could reisolate *E. durans* from experimentally infected chicks and this is similar with that reported by Devrise *et al.*; (1991) and Cardona *et al.*; (1993).

In vitro sensitivity test showed that gentamycin, ampicillin and naladixic acid were the most effective drugs against the isolated organism. We in agreement with wages (2003).

CONCLUSION:

This study prove that *E. durans* is a normal inhabitant in intestine of chickens but under certain condition or undefined factor may influence the organism to be pathogenic and chicks in the field may be infected in ovo or shortly after hatching and the numbers of bacteria may influence the formation or the severity of the lesions and increased the rate of unhatched eggs. So hyginic measures to the embryonated chicken eggs in the incubators and hatcheries may reduced the contamination with the organism.

REFERENCES:

- Alaboudi, A.R.; Hamed, D.A.; Basher, H.A and Hassen, M.(1992): Potential pathogenic bacteria from dead in shell chicken- embryos. Iraqi J. Vet. Sci. 5 : 109 -114.
- Bailey and scott's (1994): Differentiation among selected *Enterococcus* spp. and *Streptococci* and related genera. In: Diagnostic Microbiology. Section 26 p. 345, 9th Edition. Edited by: Ellen, J.B.; lance, p. R. and Sydney F.M.
- Cardona, C.J.; Bickford, A.A.; Charlton B.R. and Cooper, G.L.(1993): *Enterococcus durans* infection in young chickens associated with bacteremia and encephalomalacia. Avian Dis. 37:234-239.

- Chamanza, R.; Fabric, T.H.F., Vanveen, L. and Dwars, R.M. (1998):** Enterococcus-associated encephalomalacia in one-week old Chicks. *Vet. Rec.* 143, 450-451.
- Collins, M. D.; Jones, D.; Farrow, J.A.E.; Kilpper-Balz, R. and, Schleifer K.H. (1984):** *Enterococcus avium* nom. rev., comb. Nov.; *E. Casseliflavus* nom. rev., comb. nov. ; *E. durans* nom. rev; comb. nov.; *E. gallinarum* comb. Nov.; and *E. maloditus* sp. nov. *Int. J. System. Bacteriol.* 34 :220-223.
- Connie, M. R. and George, M. (1995):** Classification of *Streptococcus* and *Enterococcus*. In: *Diagnostic Microbiology*. P. 343-344.
- Devrise, L. A.; Hommez M, J.; Wyffels, R. and Haesebrouk F. (1991):** Composition of the Enterococcal and Streptococcal intestinal flora of poultry. *J. of Applied Bacteriology* 71:46-50.
- Facklam, R. R. and Teixeira, L. M. (1998):** *Enterococcus*. In: *Topley & Wilson's in Microbiology and Microbiol infections* chapter 29. p. 674 Vol. 2. Edited by Leslie Collier Balows, A. and Sussman, M, 9th Edition.
- Farrow, J.A.E.; Jones, D., Phillips, B.A. and Collin M.D. (1983):** Taxonomic studies on some group D *Streptococcae*. *Gen. Microbiol.* 129: 1423-1432
- Joan, S.A. and McNamee, P.T. (2002):** *Streptococci and Enterococci* In: *Poultry Diseases* P. 163-169. 5th Edition Edited by: Jordan, F., Pattison M., Alexander, D. and Faragher, T.
- Lewis, C.M. and Zervos M. J. (1990):** Clinical manifestations of Enterococcal infection. *Eur. J. Clin. Microbiol. Infect. Dis.* 9: 111-117.
- Rudy, A. (1991):** The effects of microbial Contamination of incubators on the health of broiler chicks in the first days of life. *Zesz Nauk Akad Rolniczej we Worclawian* were 49: 19-26.
- Wages, D. P. (2003):** Enterococcosis, In: *Diseases of poultry*. Chapter 24 p. 809-811. Edited by: Calnek B.W., John Barnes, H., Bread, Mcdouglad, C.W and Saif. Y. M.

عدوى ميكروب الانتيروكوكس ديورانس في الكتاكيت

هبة الله عبد الحليم محمد

باحث أول بمعهد بحوث صحة الحيوان بأسسيوط

تم جمع 90 عينة من (كبد - طحال - مخ) كتاكيت بلدي نافقة حديثاً ، ومن كتاكيت مريضة عمر 4-7 أيام (وأظهرت حركات عصبية بسيطة وخمول). تم أيضا جمع 120 بيضة كابسة من مزارع ومفرخات مختلفة بمحافظة أسسيوط. وقد أمكن عزل ميكروب الأنتيروكوكس ديورانس من الكتاكيت بنسبة (66.6%) من الكبد والطحال ونسبة (27.7%) من المخ. أيضاً تم عزل الميكروب من أجنة الكتاكيت النافقة في البيض الكابس بنسبة (70.8%) من الكبد والطحال، ومن المخ بنسبة (20.8%) مما يدل على أن الميكروب ينتقل عن طريق تلوث البيض المخصب بالميكروب من الأمهات أو عن طريق تلوثه بالزرق. وقد تم إجراء العدوى المعملية بميكروب الأنتيروكوكس ديورانس المعزول على كتاكيت بلدي سليمة عمر 1 يوم عن طريق الحقن تحت الجلد وبالعسل وبالغشاء البريتوني، والذي أدى إلى ظهور أعراض عصبية وخمول وأعراض تسمم دموي مع حدوث نفوق بنسبة 80%، 60%، 50% في الكتاكيت المعدة عن طريق الحقن في الغشاء البريتوني وبالعسل وتحت الجلد على التوالي، وأظهرت الصفة التشريحية وجود احتقانات وتضخم بالكبد والطحال وتضخم الحوصلة الصفراوية أيضاً مع وجود بقع نزفية في المخ والتهابات بالأمعاء وتضخم واحتقانات بالكلى وترسيب حمض اليوريك بالحالبين. وقد تم إعادة عزل ميكروب الأنتيروكوكس ديورانس من الحالات المعدة صناعياً وإجراء اختبار الحساسية بالميكروب المعزول وجد أن الجنتاميسين والأمبيسلين وحمض النالاديكس هي الأدوية الأكثر تأثيراً معملياً .