



## **TERATOGENIC AND GENOTOXIC EFFECTS OF PERFLUOROALKYL ACIDS ON EMBRYONIC AND NEONATE MICE**

Abd El-Nasser, M.A, Manal A. Abdel-mohsen, Shaaban A.A. and Doha Y. Ahmed

Department of Forensic Medicine and Toxicology, Faculty of Veterinary Medicine, Assiut University

---

### **ABSTRACT:**

Perfluorinated compounds (PFCs) have emerged as a new class of global environmental pollutants. Perfluorooctane sulfonate (PFOS) and perfluorooctanoic acid (PFOA) comprises a class of environmentally persistent chemicals that have a wide range of industrial applications. 160 pregnant dams were divided into two equal groups, PFOS group and PFOA group. Each group was subdivided to four equal groups (n=20), one of them was kept as control group. The first, second and third subgroups of the first main group were treated with 1, 10 and 20 mg PFOS/kg.b.w daily, respectively. While the other three subdivided groups of the second main group were treated with 1, 5 and 10 mg PFOA/kg.b.w daily. Ten dams of each group were treated from gestation day 0 (GD0) till gestation day 17 (GD17). At GD18 dams were euthanized under anesthesia. The gravid uterus were removed and examined for prenatal evaluation of fetuses. The liver of the fetuses were dissected and used immediately for comet assay. Individual live fetuses were prepared for teratological evaluation. While the other ten dams were treated from GD0 till GD18 and then allowed to give birth. The neonates of 5 dams were monitored for 4 days for postnatal survival. Neonates of the remaining 5 dams were kept in the fixative till histopathological examination. Control group were received an equivalent volume of deionized water. Prenatal finding revealed that PFOS treatment reduce the number of live fetuses accompanied with increased fetal resorption. PFOS reduced fetal body weight in a dose dependent manner, while PFOA reduced the fetal body weight at dose of 5 and 10 mg/kg b.w. Gross examination of the fetuses at GD18 showed presence of an abnormal swelling in the back of the neck in all fetuses of dams treated with 20 mg/kg b.w. Teratological evaluation revealed presence of several skeletal abnormalities in PFOS treated groups which were few in PFOA groups. Neonates were borne with reduction in body weight and showed the presence of the bilateral swelling which accompanied by neonatal death, while in PFOA treated group there was only reduction in body weight and survival rate. Results revealed that PFOS caused DNA damage in fetal liver at 10 and 20 mg/kg b.w. Histopathological examination of both, bilateral swelling and lung revealed dilatation of the blood vessels between cranial bone area and brain, and slight to sever atelectasis, respectively. The study concluded that both PFOS and PFOA were toxic to neonates with different degrees although PFOS was recorded the most toxic and the embryo might be died from the lesion formed over the brain.

---

### **INTRODUCTION:**

**Perfluorinated compounds (PFCs) have been used since the 1950s in industrial and**

commercial applications ranging from water, soil and stain resistant coating for clothing fabrics, leather, upholstery and carpets. They have also been used as oil-resistant coatings for paper products approved for food contact, electroplating, electronic etching bath, surfactants, photographic emulsifiers, aviation hydraulic fluids, fire-fighting foams, paints, adhesives, waxes and polishes. Their extensive use can be attributed to the strength of the carbon-fluorine bonds, stability at high temperatures, being nonflammable and not subject to photolysis or metabolized. PFCs are composed of a carbon-fluorine chain and generally have side moieties attached such as carboxylic acids or sulfonic acids. These compounds are respectively called perfluorinated carboxylates or perfluoroalkyl carboxylates and perfluorinated sulfonates or perfluoroalkyl sulfonates and they make up two major classes of PFCs (Giesy and Kannan, 2002). The carbon-fluorine bond in PFCs is very strong and gives thermal and chemical stability to many PFCs (So *et al.*, 2004). PFCs are now ubiquitous global contaminants. They have been detected in indoor and outdoor air, in rivers, lakes and groundwater, in wastewater treatment effluent, in landfills and in the marine environment. PFCs have also been found in the body tissues of many different living organisms throughout the world including humans (Allsopp *et al.*, 2005). Due to their widespread use, persistence and bioaccumulative properties they are taken up by the general population from different sources (Midasch *et al.*, 2007).

The reproductive toxicity of Perfluorooctane sulfonate (PFOS) has been examined in several species as rabbits (Case *et al.*, 2001), rats and mice (Lau *et al.*, 2003; and Thibodeaux *et al.*, 2003). Teratological studies have been conducted in rat, rabbit and mouse with potassium and lithium salts of PFOS (Lau *et al.*,

2003 and 2004). Observed developmental effects include reduction of fetal weight, cleft palate, edema, delayed ossification of sternum and phalanges, and cardiac abnormalities in the highest PFOS dose group. Significant reductions of weight gain and food consumption were also observed in the pregnant dams. PFOS also produced dose-dependent effects on neonatal survival and retarded the growth and development of neonates in rats exposed to doses ranging from 1–10 mg/kg/day during gestational days (GD) 2–21 and mice exposed to 1–20 mg PFOS/kg/day on GD 1 – 18 (Lau *et al.*, 2003). These effects were also reported in a two-generation study in rats exposed to doses ranging from 0.1 to 3.2 mg PFOS/kg/day (Luebker *et al.*, 2005).

In the studies by Lau *et al.* (2003), rat and mouse neonates exposed to PFOS in utero died within hours after birth, and cross-fostering of the exposed neonatal rats did not improve survival. Further studied in the rat exposed to 25 or 50 mg PFOS/kg/day on GD19 and GD 20, or to 25 mg/kg/day across various 4-day gestational intervals, demonstrated that the neonatal lethality could be produced by treatment restricted to the late gestational period and suggested that impaired lung function could be involved (Grasty *et al.*, 2005). Developmental toxicity from PFOA in rodents, including pregnancy loss, reduced fetal weight, reduced postnatal survival, and delays in postnatal growth and development in offspring were reported by Lau *et al.*, (2006). In the rat, PFOA and PFOS have been detected in placenta, fetus, amniotic fluid, and milk, and these chemicals have also been found in human breast milk (So, *et al.*, 2006).

Liu *et al.* (2007) found that PFOS and PFOA are able to produce oxidative stress (generation of ROS) and induce apoptosis and typical DNA fragmentation (DNA laddering) in

primary cultured tilapia hepatocytes. Exposure to PFOA increases the incidence of liver tumors in rodents (Biegel *et al.*, 2001). Although the mechanisms underlying this carcinogenesis have not been clarified, (Nilsson *et al.*, 1991). Peroxisome proliferation may result in elevated levels of hydrogen peroxide, which may in turn initiate tumorigenesis via oxidative DNA damage (Reddy and Rao, 1989). At the same time peroxisome proliferators may act as tumor promoters by stimulating DNA replication (Kraupp *et al.*, 1991). In addition they may inhibit the normal process of apoptosis in the liver (Schulte *et al.*, 1991). PFOA has been shown to be a strong tumor promoter, showing a 56% tumor incidence in 12 months of dietary exposure at 0.02% (w/w). Another long term feeding study in men showed that PFOA exposure at 300 ppm in the diet over 2 years increased cancers of the liver (liver adenomas) and pancreas (pancreatic acinar cell adenoma) (Olsen *et al.*, 1998).

Comet assay, known as the single-cell gel electrophoresis test used to detect DNA strand breakage (double, single, and alkali-labile sites expressed as single strand breaks) in virtually any nucleated cell. Significant advantages of the comet assay over other genotoxicity tests are its fairly straight forward technique, sensitivity, requirement for small numbers of cells and rapid production of data (Tice *et al.*, 2000). Genotoxicity of PFOA was assessed by estimating tail moment of comet in single cell gel electrophoresis (SCGE) assay (Yao and Zhong, 2005). Damaged cells have an appearance similar to astronomical comets, with long tails of DNA migrating from the center of the exposed nuclei. Damage is generally quantified using comet tail length and tail moment (i.e.: tail length multiplied by the percentage of DNA in the tail) (Tice *et al.*, 2000). Tail length can be used to indicate initial DNA damage and

confirm exposure to a genotoxin, while tail moment and percent DNA in the tail can be used to indicate the intensity of damage (Knopper *et al.*, 2005).

The aim of this work is to study the genetic and teratogenic changes in fetuses after maternal exposure to PFOS and PFOA. Histopathological examination of neonatal brain and lung and explain the cause of death was also one of research goals.

## MATERIALS AND METHODS:

### Animals:

ICR male and female mice aged 7 weeks were purchased from CLEA Japan, Inc., Tokyo were used for the experiment after one week of acclimatization. Female mice were checked for estrous cycle stage and each proestrus female was placed with an individually housed breeder male overnight, and those females with spermatozoa in its vaginal smear and/or with a copulatory plug were considered to be at gestational day 0 (GD0).

### Reagents:

**PFOS:** Perfluorooctane sulfonate (potassium salt 98% pure) was purchased from Fluka Chemie GmbH, Switzerland. PFOS solutions were prepared with a concentration of 0.1, 1 and 2 mg/ml of 0.5% Tween-20 vehicle and administered to the pregnant mice by gavage at a volume of 10 ml/kg/day

**PFOA:** Perfluorooctanoic acid (90% pure) was purchased from Fluka Chemie GmbH, Switzerland. PFOA solutions were prepared with a concentration of 0.1, 0.5 and 1 mg/ml of deionized water and administered to the pregnant mice by gavage once daily from GD0 till GD17 at a volume of 10 ml/kg/day.

## EXPERIMENTAL DESIGN:

This study protocol was approved by the Animal Research Committee. A total number of 160 pregnant dams were divided into two main equal groups. Each group was subdivided into two groups, treated group (60 dams) and control group (20 dams). Each group was subdivided to four equal groups (n=20), one of them was kept as control group. The first, second and third subgroups of the first main group were treated with 1, 10 and 20 mg PFOS/kg.b.w daily, respectively. While the other three subdivided groups of the second main group were treated with 1, 5 and 10 mg PFOA/kg.b.w daily. Ten dams of each subgroup were treated from GD0 till GD17. The gravid uterus was removed and the numbers of the live or dead fetuses and resorptions were recorded. Live fetuses were weighed individually and examined for external abnormalities. Fetuses were prepared for skeletal evaluation as described by Narotsky and Rogers (2000). The skeleton of all the stained fetuses was examined using Nikon light microscope (Model C-DSD 115, Japan) and the differences between the control and treated groups were tabulated. At parturition, newborns were weighted and observed for clinical signs and survival. The number of live pups in each litter was tabulated daily for the first 4 days after birth. Neonates head and lungs were processed routinely for paraffin embedding technique. The processed tissues were cut using tissues microtome. Tissue sections were stained with the standard Haematoxylin and Eosin method (H. & E.) according to Bancroft and Stevens (1982). while the other ten dams were treated from GD0 till GD18 and then allowed to give birth. Control group were received an equivalent volume of deionized water. At GD18 dams were euthanized under diethyl ether anesthesia. The

gravid uterus of the same dams was removed and examined for prenatal evaluation of fetuses. The liver of the fetuses were dissected and used immediately for comet assay. Individual live fetuses were prepared for teratological evaluation as described by Narotsky and Rogers (2000). The neonates of 5 dams were monitored for 4 days for postnatal survival. All the neonates of the remaining 5 dams were kept in Bouin's fixative (300 ml saturated picric acid, 100 ml formaldehyde and 20 ml glacial acetic acid) for three days then kept in 70% ethanol till histopathological examination according to Bancroft and Stevens (1982).

DNA damage in fetal liver was detected using comet assay (Single Cell Gel Electrophoresis) according to the method of Sasaki *et al.* (1997) and Tsuda *et al.* (1998). DNA damage using comet assay is generally quantified using comet tail length and tail moment, the later calculated as tail length multiplied by the percentage of DNA in the tail (Collins *et al.* 1997 and Tice *et al.*, 2000). Tail length can be used to indicate initial DNA damage and confirm exposure to a genotoxin, while tail moment and the percentage of DNA in the tail can be used to indicate the intensity of damage (Knopper *et al.*, 2005).

Data are presented as means and standard errors. Statistical significance was determined by the analysis of variance (ANOVA). Each treated group was tested for difference from the control group using Dunnett's t-test. Statistically significant differences were determined at  $p \leq 0.05$ . Statistical Package for the Social Sciences for Windows (SPSS, version 10.0, Chicago, IL, USA) according to Borenstein *et al.* (1997).

## RESULTS:

Reduction in number of live fetuses accompanied with increased fetal resorption was recorded only at 20 mg/kg b.w. PFOS group. Reduced fetal body weight in a dose dependent manner was found in all used doses as shown in table (1) while reduced fetal body weight was shown at 5 and 10 mg/kg b.w. PFOA groups. There were no significant effects on the prenatal survival or resorbed fetuses as presented in table (2).

Teratological examination of the fetuses in PFOS subgroups revealed, presence of several skeletal abnormalities such as cleft palate, delayed eruption of incisors, spina bifida occulta (delayed closure of the vertebral spin), delayed ossification of phalanges and sternum, wavy ribs, curved fetus (curved vertebral column) and abnormal tail as shown in table (1) and Fig. (1) mostly at 10 and 20 mg/kg b.w. groups, while there were few skeletal abnormalities in fetuses of PFOA group as delayed ossification of the sternum and phalanges accompanied by delayed eruption of incisors in the 10 mg/kg b.w. group (Table 2).

Gross examination of all fetuses of the 20 mg/kg b.w. PFOS subgroup at GD18 showed presence of abnormal swelling in the back of the neck region. After peeling of the skin, a bilateral firm swelling was observed. In addition, some fetuses of the 10 mg/kg b.w. group showed mild swelling in the neck region as presented in Fig. (2).

Examination of neonates born to dams treated with PFOS revealed that, the neonatal body weight was significantly reduced at 10 and 20 mg/kg b.w. groups accompanied by neonatal death (Table 3). At 20 mg/kg b.w. group, the pups were born weak, inactive and small sized then all neonates died immediately after birth (100% neonatal death). At 10 mg/kg, all pups were born alive, some pups were pale and inactive and 45% died within 24 hours after

birth, while there was no effect on the survival rate at 1 mg/kg group (Table 3), PFOA cause significant reduction in the neonatal body weight and survival rate at 5 and 10 mg/kg groups. At 5 mg/kg b.w. group all pups were born alive and active, and then 16% died during the first four days after birth. At 10 mg/kg some pups were still born and others born alive and active but all died within 6 hours after birth (100% neonatal death) (Table 3).

Gross examination of the neonates in PFOS treated subgroups revealed that, the bilateral firm swelling in the back of the neck was also observed in all neonates of 20 mg/kg b.w. dose and some neonates of the 10 mg/kg b.w.. Macroscopically, the area below the bilateral swelling appeared as a black area. In PFOA treated group, there are no abnormal structures in all the treated groups. Some neonates showed whole body edema at 10 mg/kg b.w.

DNA damage was detected in fetal liver of dams treated with PFOS at 10 and 20 mg/kg b.w., which appeared in the form of increased DNA migration represented by tail length and tail moment as shown in table (4) and Fig. (3).

Histopathologically, examination of the neonates in PFOS group showed a dilatation of vessels with blood was found between the cranial bone area and brain relevant to the black area. At a higher magnification, the dilatation was located in the Dura matter and discontinuously trimmed by the endothelial-like spindle shaped cells. Erythrocytes was found in the lumen. There were no inflammatory or hemorrhagic reactions surrounding the dilated area, indicating that the dilatation area was a blood vessel, but not hemorrhage or tumor like lesion. This dilatation of blood vessel was located either in the central part of the parietal region, near the center or in one side of the brain (Fig. 4).

Histopathological examination of neonatal lungs revealed that all neonates of the 20 PFOS mg/kg b.w. group showed severe lung atelectasis, the pulmonary architecture was destroyed, the alveolar spaces and alveolar wall could not be clearly distinguished and the alveolar epithelium was swollen and/or vacuolated in addition to congestion of the alveolar capillaries (Fig. 5). At 10 mg/kg b.w. group, some fetuses showed slight (focal) lung

atelectasis. Histopathological examination of neonatal head and lungs of PFOA subgroups revealed that some of the neonates showed slight to moderate degree of dilatation of the brain blood vessel accompanied by slight lung atelectasis at 10 mg/kg b.w. At 5 mg/kg b.w., some neonates showed slight dilatation of brain blood vessel and no changes in lungs. There were no changes in all the examined samples at 1 mg/kg b.w..

Table (1): Teratogenic effects of PFOS in fetuses

Parameters	Control	Concentration (mg/kg b.w.)		
		1 mg	10 mg	20 mg
Total number of fetuses (N)	139	140	130	121
Fetus body weight (g)	1.49 ± 0.01	1.44 ± 0.01*	1.39 ± 0.01*	1.07 ± 0.01**
Live fetus (%)	99.21 ± 0.78	98.46 ± 1.01	97.50 ± 1.26	87.31 ± 2.58**
Resorbed fetuses (%)	0.78 ± 0.78	1.52 ± 1.00	2.49 ± 1.26	7.25 ± 2.56*
Dead fetuses (%)	0	0	0	5.43 ± 2.40**
Cleft Palate (%)	0	1.96 ± 1.96	26.36 ± 8.27**	98.56 ± 1.44**
Sternal cleft (%)	0	15.77 ± 0.99**	52.44 ± 2.79**	100**
Delayed ossification of Phalanges (%)	0	1.96 ± 1.96	4.34 ± 1.80	57.23 ± 9.60**
Delayed eruption of incisors (%)	3.25 ± 1.89	6.90 ± 0.53	22.12 ± 2.68**	36.08 ± 4.64**
Extra ribs (%)	27.81 ± 13.35	13.01 ± 6.59	36.11 ± 11.85	32.08 ± 8.04
Wavy ribs (%)	0	0	7.31 ± 0.34*	84.09 ± 2.56**
Abnormal tail (%)	4.41 ± 4.41	18.38 ± 8.73	23.05 ± 3.25	65.00 ± 6.71**
Curved fetus (%)	3.55 ± 2.11	4.94 ± 2.47	33.38 ± 8.47**	68.47 ± 1.30**
Spina bifida occulta (%)	0	1.96 ± 1.96	23.13 ± 3.94**	100**

Table (2): Teratogenic effect of PFOA in fetuses

Parameters	Control	Concentration (mg/kg b.w.)		
		1 mg	5 mg	10 mg
Total number of fetuses (N)	130	120	107	101
Fetus body weight (g)	1.47 ± 0.01	1.53 ± 0.01**	1.36 ± 0.01**	1.06 ± 0.01**
Live fetus (%)	98.97 ± 1.02	99.34 ± 0.65	97.12 ± 1.76	94.77 ± 2.69
Resorbed fetuses (%)	1.02 ± 1.02	0.65 ± 0.65	2.85 ± 1.74	1.47 ± 0.96
Dead fetuses (%)	0	0	0	3.73 ± 2.13
Cleft Palate (%)	0	0	0	4.99 ± 3.33
Sternal cleft (%)	1.25 ± 1.25	0	8.68 ± 6.91	55.24 ± 18.23*
Delayed ossification of Phalanges (%)	2.50 ± 2.50	1.11 ± 1.11	16.04 ± 11.20	47.65 ± 17.15*
Delayed eruption of incisors (%)	2.50 ± 2.50	0	15.93 ± 12.44	44.8 ± 19.91*
Extra ribs (%)	6.78 ± 3.65	1.38 ± 1.38	20.97 ± 6.70	15.74 ± 7.70
Abnormal tail (%)	11.25 ± 6.9	2.30 ± 1.45	4.41 ± 1.81	9.58 ± 8.11

Table (3): Effects of PFOS and PFOA on body weight and survival percent of neonates

Substance	Concentration.	Number of pups (N)	Neonatal Body weight (g)	Survival rate (%)
PFOS	Control	73	1.50 ± 0.02	98.10 ± 1.80
	1 mg/kg b.w.	76	1.54 ± 0.01	100
	10 mg/kg b.w.	71	1.44 ± 0.01*	55.20 ± 18.9*
	20 mg/kg b.w.	60	1.08 ± 0.01**	0**
PFOA	Control	76	1.63 ± 0.01	98.00 ± 2.00
	1 mg/kg b.w.	70	1.66 ± 0.01	100
	5 mg/kg b.w.	61	1.50 ± 0.02**	84.40 ± 5.54**
	10 mg/kg b.w.	58	1.16 ± 0.02**	0**

Table (4): Genetic effects of PFOS in fetal liver DNA migration and tail moment

Parameter	Control	Concentration (mg/kg b.w.)		
		1 mg	10 mg	20 mg
DNA migration (µm)	11.13 ± 0.97	11.06 ± 0.77	25.27 ± 1.60**	25.93 ± 1.46**
Tail moment (µm)	1.07 ± 0.23	1.06 ± 0.18	3.02 ± 0.38**	3.45 ± 0.41**

Data represent mean ± SE. Significant difference (\*\*p<0.01) between control and treatment groups.




Fig. (1): Skeletal abnormalities in fetuses of mice exposed to PFOS. A) Control, B) treated, 1. cleft palate,

2. delayed eruption of incisors, 3. spina bifida occulta, 4. delayed ossification of phalanges,
5. delayed ossification of sternum, 6. wavy ribs, 7. curved fetus, 8. abnormal tail. 9. extra ribs.

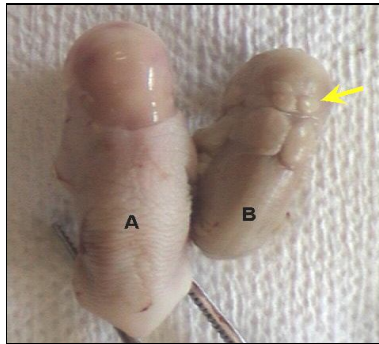


Fig. (2): Mice fetuses from the control (A) and 20 mg/kg PFOS Groups (B), showing bilateral swelling at the neck (arrow)

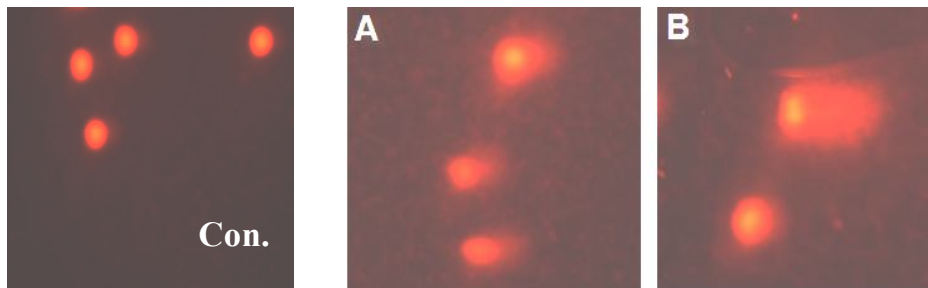


Fig. (3): Image of an alkaline comet (hepatocytes) stained with ethidium bromide showing undamaged nucleus (control) and damaged nucleus, A) Partially damaged, B) Severely damaged

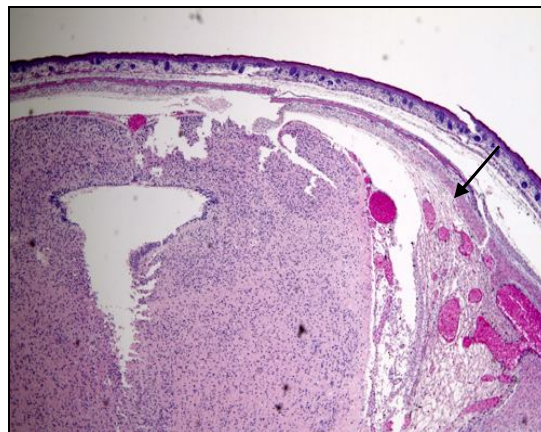


Fig. (4): Transverse section of fetus head of mouse exposed to 20 mg/kg PFOS. The arrow shows intracranial blood vessel dilatation (arrow)



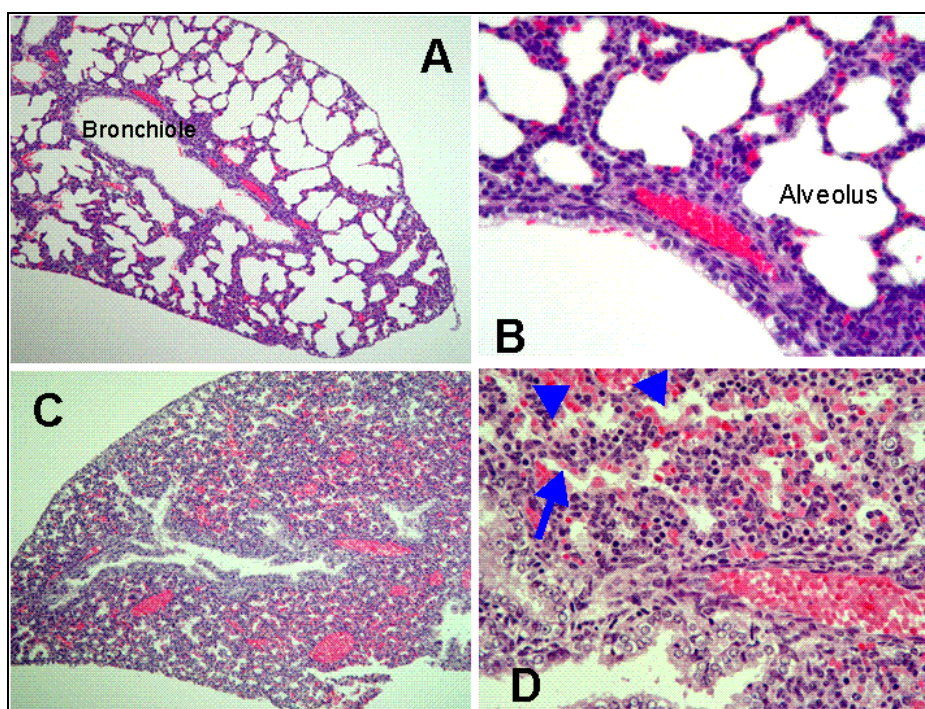


Fig. (5): Representative micrograph showing lung histology of newborn mice (immediately after birth) in the control and 20 mg/kg PFOS treated groups; A and B) control lung showing normal air filled alveoli (100X (A) and 400X (B). C) atelactic lung (100X) D) atelactic lung showing slit like alveoli (arrow) and congestion of alveolar capillaries (arrow head) (400X).

## DISCUSSION:

PFCs have recently received attention due to their widespread contamination in the environment, wildlife and humans (Houde *et al.*, 2006 and Calafat *et al.*, 2007). PFOS and PFOA are the most widely detected and studied compounds in this class. The levels of PFOS and PFOA have been increasing more and more in global oceans.

Maternal exposure to PFOS during pregnancy reduced the number of live fetuses and increased fetal resorption only at 20 mg/kg group, while reduced the fetal body weight in a dose dependent manner as the following  $1.44 \pm 0.01$ ,  $1.39 \pm 0.01$  and  $1.07 \pm 0.01$  gm at 1, 10 and

20 mg/kg b.w. treated groups respectively. While the fetal body weight only was significantly reduced after exposure to PFOA in the following manner  $1.36 \pm 0.01$  and  $1.06 \pm 0.01$  gm at 5 and 10 mg/kg b.w. groups. The decrease in fetal body weight after exposure to PFOS and PFOA is similar to findings that recorded by Case *et al.* (2001) in rabbits, Thibodeaux *et al.* (2003) in rats and Lau *et al.* (2006) in mice.

The presence of an abnormal bilateral swelling in the back of the neck region in all fetuses of the 20 mg/kg b.w. of PFOS treated group and in some fetuses of the 10 mg/kg b.w. treated group which considered the first record in this respect as showed in Fig. (2). Other skeletal abnormalities recorded for the first

time such as delayed eruption of incisors, spina bifida occulta, wavy ribs, curved vertebral column, and abnormal tail were found mostly in the 20 mg/kg b.w. PFOS group and which presented in Plate (1).

The present study showed that maternal exposure to PFOS caused skeletal abnormalities as cleft palate and delayed ossification of the sternum and phalanges which are similar to previous studies in rats (Henwood *et al.*, 1994), rabbit (Case *et al.*, 2001) and mice (Thibodeaux *et al.*, 2003). These findings were the same between laboratories and across species examined. Observed developmental effects included reduction of fetal weight, cleft palate, delayed ossification of bones (sternbrae and phalanges), anasarca (edema) and cardiac abnormalities (ventricular septal defects and enlargement of the right atrium). Nonetheless, it should be noted that a preponderance of these structural abnormalities was found in the highest PFOS dose groups (10 mg/kg for the rat and 20 mg/kg in the mouse) Lau *et al.* (2004).

Maternal exposure to PFOA resulted in few skeletal anomalies as delayed ossification of the sternum and phalanges accompanied by delayed eruption of incisors in the 10 mg/kg b.w. treated group. These findings contradict the findings reported by Lau *et al.* (2004) who stated that PFOA had no teratogenic effect in mice and Butenhoff *et al.* (2004) who found no structural changes in rat skeleton after exposure to 10 mg/kg PFOA. Teratological changes in fetal skeleton recorded in this study were more obvious in the PFOS treated groups than that of PFOA groups.

PFOS and PFOA reduced the survival rate of the neonates; there was a 100% neonatal mortality (all neonates died immediately after birth) at 20 mg/kg b.w. PFOS and 10 mg/kg b.w. PFOA. PFOA is shown more toxic for the offspring than PFOS because 100% neonatal

mortality occurred at 10 mg/kg b.w. PFOA; while, 45% neonatal mortality occurred at the same dose of PFOS. Furthermore, almost all neonates of the 10 mg/kg b.w. PFOA treated group were active and viable at time of birth then died within 6 hours after birth. Similar studies conducted on mice (Lau *et al.*, 2003) and rats (Luebker *et al.*, 2005), revealed that exposure to PFOS produced dose dependent effects on neonatal survival. Lau *et al.* (2003) examined the effect of PFOS on the survival rate in mice and rats and recorded that, in the highest dosage (10 mg/kg b.w. of rat and 20 mg/kg b.w. of mouse), the neonates became pale, inactive, and moribund within 30–60 min, and all died soon afterward. In the 5 mg/kg (rat) and 15 mg/kg (mouse) dosage groups, the neonates also became moribund but survived for a longer period of time (8–12 h). Over 95% of these animals died within 24 h. Approximately 50% of offspring died at 3 mg/kg for rat and 10 mg/kg for mouse. Cross fostering the PFOS exposed rat neonates (5 mg/kg) to control nursing dams failed to improve survival. Lau *et al.* (2006) stated that the postnatal survival was severely compromised in mice exposed to 10 mg/kg PFOA, furthermore Wolf *et al.* (2007) reported that exposure of mice to PFOA affects growth, development and viability of offspring.

Some studies referred to the cause of neonatal death in rats. Grasty *et al.* (2003) reported that exposure of rat to PFOS late in gestation (GD19-GD20) is sufficient to induce 100% pup mortality and that the causative factor may be inhibition of lung maturation. Later, Grasty *et al.* (2005) studied the lung maturation in prenatal rats, and they found that the pulmonary surfactant profile was normal and rescue agents (dexamethasone and retinyl palmitate) failed to increase the postnatal survival. They concluded that lung immaturity was not the cause of neonatal death in exposed

rats.

Although the mechanisms underlying the carcinogenesis of PFOS and PFOA have not been clarified, a number of hypotheses have been proposed. Peroxisome proliferation may result in elevated levels of hydrogen peroxide, which may in turn initiate tumorigenesis via oxidative DNA damage (Reddy and Rao, 1989). At the same time peroxisome proliferators may act as tumor promoters by stimulating DNA replication (Kraupp *et al.*, 1991). In addition they may inhibit the normal process of apoptosis in the liver (Schulte *et al.*, 1991). PFOS and PFOA have been found to cause hepatic peroxisome proliferation (Berthiaume and Wallace, 2002).

Our results indicated that PFOS had genotoxic effects on hepatic cells because these compounds induced remarkable DNA damage in hepatic cells. Significant increase in tail length (DNA migration) and tail moment were recorded in fetal hepatic cells exposed to PFOS. The increased tail length in fetal liver were  $25.27 \pm 1.60$  and  $25.93 \pm 1.46$  and tail moment was  $3.02 \pm 0.38$  and  $3.45 \pm 0.41$  in the 10 and 20 mg/kg PFOS treated subgroups respectively. Meanwhile maternal exposure to PFOA has no significant indication in fetal tail length or tail moment.

In Histopathological examination of 20 mg/kg b.w. PFOS group, all fetuses at GD18 showed intracranial blood vessel dilatation and severe lung collapse (atelectasis), and after birth all neonates showed the intracranial blood vessel dilatation (Fig. 4) and severe lung atelectasis (Fig. 5). In the 10 mg/kg b.w. dosage group, some pups showed slight lung atelectasis, some showed mild to severe dilatation of brain blood vessel. In addition, all the pups having slight atelectasis also showed moderate to severe intracranial blood vessel dilatation. One of the

probable explanations for the neonatal death might be that the intracranial blood vessel dilatation press on the respiratory center of the brain and prevent the lungs to start respiration after birth which agreement with Doha, *et. al.* (2008) who stated that the cause of neonatal death of mice may be attributed either to the intracranial dilatation of the blood vessels or to the sever pulmonary dysfunction, and the former might be a cause for the latter. In PFOA group, neonatal brain and lung revealed mild dilatation of brain blood vessel and slight collapse of the lung. In spite of the fact that PFOS and PFOA are similar in causing neonatal death but the cause of death may be different. Further studies are required to explore the cause of neonatal death after maternal exposure to PFOS and PFOA.

#### Acknowledgment:

The authors wish to thank Professor Dr. Shuji Tsuda, Professor of Veterinary Public Health, School of Veterinary Medicine, Faculty of Agriculture, Twate University, Japan and Professor Dr. Midori Yoshida, Professor of Pathology, Biological Safety Center, National Institute of Health Science, Japan for their assistance and advice during this work.

#### REFERENCES:

- Allsopp, M.; Santillo, D.; Walters, A. and Johnston, P. (2005): Perfluorinated chemicals: an emerging concern. Greenpeace Research Laboratories Technical Note. Department of Biological Sciences, University of Exeter, Exeter EX4 4PS, UK, pp. 1-45.
- Bancroft, J. D. and Stevens, A. (1982): Theory and Practice of Histopathological Techniques. pp. 134. 2nd Ed. Charchill Living Stone EdinBurgh London

- Melbourne and New York.
- Berthiaume, J. and Wallace, K. B. (2002): Perfluorooctanoate, perfluorooctane sulfonate, and N-ethyl perfluorooctane sulfonamido ethanol; peroxisome proliferation and mitochondrial biogenesis. *Toxicol. Lett.* 129: 23–32.
- Biegel, L. B.; Hurtt, M. E.; Frame, S. R.; O'Connor, J. C. and Cook, J. C. (2001): Mechanisms of extrahepatic tumor induction by peroxisome proliferators in male CD rats. *Toxicol Sci.* 60: 44–55.
- Borenstein, M.; Rothstein H, and Cohen. J. (1997): Sample power statistics 1.5. SPSS I. N. C. Chicago.
- Butenhoff, J. L.; Kennedy, G. L.; Frame, S. R.; O'Connor, J. C. and York, R. G. (2004): The reproductive toxicology of ammonium perfluorooctanoate (APFO) in the rat. *Toxicology* 196: 95-116.
- Calafat, A. M.; Kuklenyik, Z.; Reidy, J. A.; Caudill, S. P.; Tully, J. S.; Needham, L. L. (2007): Serum concentrations of 11 polyfluoroalkyl compounds in the U.S. population: data from the National Health and Nutrition Examination Survey (NHANES) 1999–2000. *Environ. Sci. Technol.* 41: 2237–2242.
- Case, M. T.; York, R. G. and Christian, M. S. (2001): Rat and rabbit oral developmental toxicology studies with two perfluorinated compounds. *Int. J. Toxicol.* 20: 101–109.
- Collins, A. R.; Dobson, V. L.; Dusinská, M.; Kennedy, G. and Stětina, R. (1997): The comet assay: what can it really tell us?. *Mutat. Res.* 375 (2): 183-193.
- Doha, Y. Ahmed, Tsukuba, C., Yoshida, M., Sato, I. and Tsuda, S. (2008): Neonatal death of mice treated with perfluorooctane sulfonate. *The Journal of toxicological Sciences*, vol. 33, No. 2, 219 – 226.
- Giesy, J. P. and Kannan, K. (2002): Perfluorochemical surfactants in the environment. *Environ. Sci. Technol.* 36 (7): 146A-152A.
- Grasty, R. C.; Grey, B. E.; Lau, C. S. and Rogers, J. M. (2003): Prenatal window of susceptibility to perfluorooctane sulfonate-induced neonatal mortality in the Sprague Dawley rat. *Birth Defects Res. B Dev. Reprod. Toxicol.* 68: 465–471.
- Grasty, R. C.; Bjork, J. A.; Wallace, K. B.; Lau, C. S. and Rogers, J. M. (2005): Effects of prenatal perfluorooctane sulfonate (PFOS) exposure on lung maturation in the perinatal rat. *Birth Defects Res. B Dev. Reprod. Toxicol.* 74: 405–416.
- Henwood, S. M.; McKee-Pesick, P.; Costello, A. C.; and Osmitz, T. G. (1994): Developmental toxicity study with lithium perfluorooctane sulfonate in rats. *Teratology* 49: 398.
- Houde, M.; Martin, J. W.; Letcher, R. J.; Solomon, K. R. and Muir, D. C. (2006): Biological monitoring of polyfluoroalkyl substances: a review. *Environ. Sci. Technol.* 40: 3463–3473.
- Knopper, L. D.; Mineau, P.; McNamee, J. P. and Lean, D. R. (2005): Use of comet and micronucleus assays to measure genotoxicity in meadow voles (*Microtus pennsylvanicus*) living in golf course ecosystems exposed to pesticides. *Ecotoxicology* 14 (3): 323-335.
- Kraupp, G. B.; Huber, W.; taper, H. and Schulte, H. R. (1991): Increased susceptibility of aged rats to hepatocarcinogenesis by the peroxisome proliferator nafenopin and the possible involvement of altered liver foci occurring spontaneously. *Cancer Res.* 51:

- 237-244
- Lau, C.; Thibodeaux, J. R.; Hanson, R. G.; Rogers, J. M.; Grey, B. E.; Stanton, M. E.; Butenhoff, J. L. and Stevenson, L. A. (2003): Exposure to perfluorooctane sulfonate during pregnancy in rat and mouse. II: Postnatal evaluation. *Toxicol. Sci.* 74: 382–392.
- Lau, C.; Butenhoff, J. L. and Rogers, J. M. (2004): The developmental toxicity of perfluoroalkyl acids and their derivatives. *Toxicol. Appl. Pharmacol.* 198: 231–241.
- Lau, C.; Thibodeaux, J. .; Hanson, R. G.; Narotsky, M. G.; Rogers, J. M.; Lindstrom, A. B. and Strynar, M. J. (2006): Effects of perfluorooctanoic acid exposure during pregnancy in the mouse. *Toxicol. Sci.* 90: 510–518.
- Liu, C.; Yu, K.; Shi, X.; Wang, J.; Lam, P. K.; Wu, R. S. and Zhou, B. (2007): Induction of oxidative stress and apoptosis by PFOS and PFOA in primary cultured hepatocytes of freshwater tilapia (*Oreochromis niloticus*): *Aquatic Toxicology* 82: 135–143.
- Luebker, D. J.; York, R. G.; Hansen, K. J., Moore, J. A. and Butenhoff, J. L. (2005): Neonatal mortality from in utero exposure to perfluorooctanesulfonate (PFOS) in Sprague-Dawley rats: doseresponse, and biochemical and pharmacokinetic parameters. *Toxicology* 215:149–169.
- Midasch, O.; Drexler, H.; Hart, N.; Beckmann, M. W. and Angerer, J. (2007): Transplacental exposure of neonates to perfluorooctanesulfonate and perfluorooctanoate: a pilot study. *Int. Arch. Occup. Environ. Health* 80: 643–648.
- Narotsky, M. G. and Rogers, J. M. (2000): Examination of the axial skeleton of fetal rodents. In: *Developmental Biology Protocols Vol. I* (R. S. Tuan and C. W. Lo, Eds.), Humana Press, New Jersey. pp. 139–150
- Nilsson, R.; Beije, B.; Preat, V.; Erixon, K. and Ramel, C. (1991): On the mechanism of the hepatocarcinogenicity of peroxisome proliferators. *Chem. Biol. Interact.* 78: 235-250.
- Olsen, G. W., Gilliland, F.D., Burlew, M.M., Burris, J.M., Mandel, J.S. and Mandel, J.H. (1998): An epidemiologic investigation of reproductive hormones in men with occupational exposure to perfluorooctanoic acid. *J. Occup. Environ. Med.* 40: 614–622.
- Reddy, J. K. and Rao, M. S. (1989): Oxidative DNA damage caused by persistent peroxisome proliferation: its role in hepatocarcinogenesis. *Mutat. Res.* 214: 63-68.
- Sasaki, Y. F.; Izumiyama, F.; Nishidate, E.; Matsusaka, N. and Tsuda, S. (1997): Detection of rodent liver carcinogen genotoxicity by the alkaline single cell gel electrophoresis (Comet) assay in multiple mouse organs (liver, lung, spleen, kidney and bone marrow). *Mutat. Res.* 391: 201-214.
- Schulte, H. R.; Bursch, W. and Parzefall, W. (1991): Mitogenesis and programmed cell death as determinants of carcinogenicity of nongenotoxic compounds. *Prog. Clin. Biol. Res.* 369: 237-244.
- So, M. K.; Taniyasu, S.; Yamashita, N.; Giesy, J. P.; Zheng, J.; Fang, Z.; Im, S. H. and Lam, P. K. S. (2004): Perfluorinated compounds in coastal waters of Hong Kong, South China, and Korea. *Environ. Sci. Technol.* 38 (15): 4056-4063.
- So, M. K.; Yamashita, N.; Taniyasu, S.; Jiang,

- Q.; Giesy, J. P.; Chen, K. So, M. K.; Yamashita, N.; Taniyasu, S.; Jiang, Q.; Giesy, J. P.; Chen, K. and Lam, P. K. (2006): Health risks in infants associated with exposure to perfluorinated compounds in human breast milk from Zhoushan, China. *Environ. Sci. Technol.* 40: 2924–2929.
- Thibodeaux, J. R.; Hanson, R. G.; Rogers, J. M.; Grey, B. E.; Barbee, B. D.; Richards, J.H.; Butenhoff, J.L.; Stevenson, L.A. and Lau, C. (2003): Exposure to perfluorooctane sulfonate during pregnancy in rat and mouse. I: Maternal and prenatal evaluations. *Toxicol. Sci.* 74: 369–381.
- Tice, R. R.; Agurell, E.; Anderson, D.; Burlinson, B.; Hartmann, A.; Kobayashi, H.; Miyamae, Y.; Rojas, E.; Ryu, J. C. and Sasaki, Y. F. (2000): Single cell gel/comet assay: guidelines for in vitro and in vivo genetic toxicology testing. *Environ. Mol. Mutagen.* 35 (3): 206-221.
- Tsuda, S.; Kosaka, Y.; Matsusaka, N. and Sasaki, Y. F. (1998): Detection of pyrimethamine-induced DNA damage in mouse embryo and maternal organs by the modified alkaline single cell gel electrophoresis assay. *Mutat. Res.* 415: 69-77.
- Wolf, C. J.; Fenton, S. E.; Schmid, J. E.; Calafat, A. M.; Kuklenyik, Z.; Bryant, X. A.; Thibodeaux, J.; Das, K. P.; White, S. S.; Lau, C. S. and Abbott, B. D. (2007): Developmental toxicity of perfluorooctanoic acid in the CD-1 mouse after crossfoster and restricted gestational exposures. *Toxicol. Sci.* 95: 462-73.
- Yao, X. and Zhong, L. (2005): Genotoxic risk and oxidative DNA damage in HepG2 cells exposed to perfluorooctanoic acid. *Mutat Res.* 587 (1-2): 38-44.

## تأثير أحماض بيرفلوروالكيل على الأجنة والجرذان حديثة الولادة

محمود عبد الناصر على، منال عبد اللطيف عبد المحسن،

عبد العزيز أحمد شعبان، ضحى يحيى أحمد

قسم الطب الشرعي والسموم - كلية الطب البيطري - جامعة أسيوط - مصر

تم في هذه الدراسة استخدام 160 انثى جرذ أبيض حامل. تم تقسيمها إلى مجموعتين متساويتين. قسمت كل منهما إلى مجموعتين: الأولى 60 جرذ كمجموعة معالجة والتي قسمت بعد ذلك إلى ثلاث مجموعات متساوية ليتم تجريعها 1 و 10 و 20 مجم لكل كيلو من وزن الجسم من مادة البيرفلوروأوكتان سلفونيت (PFOS) و 20 جرذ كمجموعة ضابطة. كذلك قسمت المجموعة الثانية إلى 60 جرذ كمجموعة معالجة والتي تم إعادة تقسيمها إلى ثلاث مجموعات فرعية متساوية ليتم تجريعها 1 و 5 و 10 مجم لكل كيلو من وزن الجسم من مادة البيرفلوروأوكتانويك (PFOA) و 20 جرذ كمجموعة ضابطة. تم معالجة عشر جرذان حوامل من كل مجموعة فرعية من اليوم الأول للحمل وحتى اليوم السابع عشر وفي اليوم الثامن عشر تخديرها لاستخراج الرحم وفحص الأجنة. تم تجميع كبد الأجنة وأجراء فحص المادة الوراثية. بينما عولجت العشر الأخرى من اليوم الأول حتى اليوم الثامن عشر ثم تركت حتى الولادة. تم ملاحظة المواليد الخاصة بنصف الأمهات لمدة أربعة أيام عقب الولادة وتسجيل الوفيات. بينما تم تجميع الولادات الخاصة بالنصف الآخر وأعدادها للفحص الباثولوجي. أظهرت النتائج وجود تلف في المادة الوراثية في خلايا كبد الأجنة التي تعرضت إلى PFOS بنسبة 10 و 20 مجم لكل كيلو من وزن الجسم. كذلك تسببت في نقص عدد الجرذان الحية في الرحم مع زيادة في عدد الأجنة الممتصة. وكان وزن الأجنة يتناقص طرديا مع زيادة الجرعة من نفس المادة بينما كان التأثير واضحا في مادة PFOA عند الجرعات 5 و 10 مجم لكل كيلو من وزن الجسم. وعند الفحص الظاهري للأجنة وجد انتفاخ واضح خلف الرقبة في كل الأجنة للأمهات المعالجة ب 20 مجم لكل كيلو من مادة PFOS ووجود العديد من التشوهات في الهيكل العظمي للأجنة بينما قلت هذه التشوهات في الأجنة التي عولجت بمادة PFOA. وعند فحص الجرذان المولودة حديثا للأمهات عولجت ب 10 و 20 مجم لكل كيلو من الوزن من PFOS وجد انخفاض معنوي في وزنها وموتها مع وجود الانتفاخ خلف الرقبة. بينما في المجموعة التي عولجت بمادة PFOA بنسبة 5 و 10 مجم لكل كيلو من الوزن لوحظ انخفاض في وزن المواليد وكذلك نسبة النفوق كما لوحظ عدم وجود الانتفاخ خلف الرقبة. وعند الفحص الباثولوجي لكل من الانتفاخ والرئة للمواليد وجد اتساع في الأوعية الدموية ما بين عظام الجمجمة والمخ مع وجود ضيق في الحويصلات الهوائية بالرئة. وأمكن من الدراسة استنتاج أن كل من المادتين تحت التجربة لها تأثير سام على الأجنة والمواليد بدرجات مختلفة لأن كانت مادة PFOS أكثر سمية للأمهات و PFOA أكثر سمية للأجنة.