



## **SOME STUDIES ON METACERCARIAL INFECTION IN *Oreochromis niloticus* IN ASSIUT GOVERNORATE AND THEIR ROLE IN TRANSMISSION OF SOME TREMATODES TO DOGS**

Gamal Ameen Taher

Parasitological Unit, Animal Health Research Institute, Assiut Lab

---

### **ABSTRACT:**

A total number of 400 *Oreochromis niloticus* (*Tilapia nilotica*) were investigated for parasitological studies on various encysted metacercariae of digenetic trematodes in different body parts of the examined fish specimens in Assiut Governorate. The total prevalence of infected *Oreochromis niloticus* with different encysted metacercariae was 84.75%. They were differentiated into two types: The first type was microscopic encysted metacercariae, their prevalence rate was 78.25%. They were distributed between muscle fibers of the trunk, tail and head regions. The second one was clinostomatid metacercariae, their prevalence rate was 62.25%. The branchial chamber was the most common habitat of infection where their infection rate was 47.5% followed by kidneys 13.25% then skin 1.5%. The detected clinostomatid metacercariae were differentiated into four species: *Clinostomum phalacrocoracis*, *Clinostomum tilapiae*, *Euclinostomum ardeolae* and *Euclinostomum heterostomum*. Microscopic encysted metacercariae were differentiated into *Prohemistomum vivax* and *Haplorchis spp.* The incidence, distribution and intensity of the encysted metacercariae in different regions of the examined fish were studied. Experimental infection was carried out to confirm the identification of different kinds of microscopic encysted metacercariae by feeding parasite free puppies with different encysted metacercariae collected from the muscles of *Oreochromis niloticus*. Two types of adult digenetic trematodes were recovered from the intestinal mucosa (5-7 days post infection): The first type is *Prohemistomum vivax* and the second type is *Haplorchis yokogawai*.

---

### **INTRODUCTION:**

Digenetic trematodes and their metacercariae take a great interest in most countries especially for the human care against the transmissible diseases. They were considered as one of the most common parasites infecting fish causing low weight gain, high mortality, immarketability and some of these parasites may have zoonotic importance

(Hernandez *et al.*, 1998). They occur in a number of fish hosts and possess a complex life cycles involving a number of hosts with several successive larval generations. In general, the life cycle involves a snail first intermediate host, a fish second intermediate host and a final vertebrate host (Svobodova & Kolarova 2004). The public health importance of some internal parasitic diseases affecting *Tilapia nilotica* such

as yellow grub disease which can be transmitted to human as a result of ingesting raw or improperly cooked fish and causing Halzoun like disease leading to laryngo-pharyngitis while *Prohemistomum vivax* was rarely recorded to infect human and may cause death (Williams and Jones, 1976 and Nasr,1941). Heterophyid metacercariae cause severe gill damage, decrease respiratory tolerance and mortality in pond raised fish in the subtropics and tropics (Paperna, 1991).The known methods for the identification of microscopic metacercariae are using suitable hosts for experimental infection as metacercariae have no mature reproductive organs. It is usually very difficult to identify metacercariae for different species (Noga, 2000). Therefore the present work aimed to investigate the prevalence, density and distribution of the different encysted metacercariae in *Oreochromis niloticus*. In addition to assess the role played by such fish in transmission of some trematodes to dogs using biological studies.

## **MATERIAL AND METHODS:**

### **1- Samples:**

A total number of 400 specimens of *Oreochromis niloticus* (75±25 gm body weight) were randomly collected from different localities of the River Nile at Assiut Governorate.

### **2- Parasitological examination:**

a-The specimens under investigation were carefully examined by the naked eye for detection of encysted metacercariae in skin, fins, musculature and gills. Microscopic examination was carried out by taking small snips of the muscles from different regions of the body (head, trunk and tail), each snip was compressed between two glass slides and examined under a binocular dissecting

microscope. The prevalence of infection was estimated (Shalaby 1985).

b-Determination of the density of infection with microscopic encysted metacercariae. The density of infection in the three different regions was recorded in 10% of the fish by examining one gram of muscle tissue from each one, divided into small pieces, pressed between two slides and encysted metacercariae were counted (El-Naffar and El-Shahawi 1986).

c-Excystation of metacercariae: Excystation of the encysted metacercariae was carried out by dissecting needles under a binocular dissecting microscope. Infected specimens of fish were minced and artificially digested with 0.25% pepsin in 0.85% NaCl for one hour at 37°C in shaking water bath (Srisawangwong *et al.*, 1997). The digested tissues were strained through sieves and sedimented in 0.85% NaCl. The investigated encysted metacercariae were separated under the binocular microscope according to their morphological characters. Each kind of collected metacercariae was used to infect single experimental host. The excysted larvae were fixed, stained by acetic acid alum carmine and mounted in Canada balsm (Kruse & Pritchard 1982).

### **3-Biological studies:**

In a trial to get the adults of the obtained microscopic encysted metacercariae, experimental infection of three six weeks old parasite free puppies was done by feeding each one singly with each separated kind of microscopic encysted metacercaria. Another two parasite free puppies were kept as control. Daily faecal samples were examined by the sedimentation technique for the determination of the prepatent period.

Experimentally infected puppies were sacrificed within 10 days from the day of infection to collect the adult worms from their intestinal tract. The collected trematode worms were washed in normal saline, relaxed in refrigerator, fixed in 4% formalin, carmine stained and permanently mounted (Shalaby 1982). Identification of different detected metacercariae and adult worms was done according to the key given by Yamaguti (1958) and Ukoli (1966). The detected metacercariae and adult worms were measured by the use of eyepiece micrometer and photomicrographed by using dissecting microscope.

## RESULTS:

Out of 400 examined *Oreochromis niloticus* 339 were infected with one or more species of encysted metacercariae with overall prevalence rate 84.75%. Two forms of metacercariae were detected in the present work:

- 1-Microscopic encysted metacercariae with a prevalence rate 78.25%.
- 2-Macroscopic encysted metacercariae (clinostomatid metacercariae), their prevalence rate was 62.25% (Table 1).

### 1-Microscopic encysted metacercariae:

It was found that out of 400 specimens of *O. niloticus*, 313 (78.25%) were infected with one or more species of microscopic encysted metacercariae (Table 2). The metacercariae were found in the muscles all over the body especially in head, trunk and caudal regions.

Three types of microscopic encysted metacercariae were met within the present study, two of which were identified according to (Fahmy *et al.*, 1980 and El-Shahawi 1983) as *Prohemistomum vivax* and *Haplorchis spp.* metacercariae, other metacercariae could not be identified (Plate 3). Mixed infection by more

than one type of metacercariae was detected (Table 2).

The density of the microscopic encysted metacercariae was represented by the number of metacercariae per gram of muscle tissue. It was higher in the trunk region which ranged between 65-115 (92) metacercariae, then the tail region which had 55-98 (81) metacercariae and lastly the head region especially near the base of the pectoral fins which was represented by 42-77(65) metacercariae per gram tissue (Table 3).

Metacercariae encountered in the muscles of *Oreochromis niloticus* were:

### **a-Metacercariae of *Prohemistomum vivax*:**

They were found in the muscles of the head, trunk and caudal regions of *Oreochromis niloticus*, their rate of infestation was 72.25% (Table 2).

### **Morphology of the encysted metacercariae: (Based on 6 encysted metacercariae)**

These are moderate sized cysts measuring 300-320 by 310-345 microns. They are spherical or subspherical, double walled, outer thick and inner hyaline and separated from the metacercaria by a potential space containing fluid in which the metacercaria was moving, pigmented granules and vacuoles were present in this space. Cysts were surrounded by a thick layer of infiltrated cells, the layer differed in thickness at different levels (Plate 3, a). The metacercaria was usually folded inside its cyst wall (Plate 3, a). Excystation of some encysted metacercariae and their extrusion from the cysts was observed (Plate 3, b).

### **b-Metacercariae of *Haplorchis spp.*:**

They were detected in the muscles of the head, trunk and tail regions of *O. niloticus*. Rate of infection was 26% (Table 2).

The encysted metacercariae were scattered in between the muscle fibers of fish host. Inside the cyst the metacercariae were usually rolling or curled.

#### **Morphology of the encysted metacercariae: (Based on 5 encysted metacercariae)**

The cysts were ovoid in shape and small in size measuring 152-173 µm in length and 125-155 µm in breadth. They were not surrounded by any tissue reaction. They were surrounded by a thick cyst wall measuring about 1.3 µm. The metacercaria was characterized by possessing a black excretory vesicle filled with the excretory granules at the caudal end (Plate 3, c).

#### **2-Clinostomalid metacercariae:**

Examination of 400 specimens of *O. niloticus* revealed that (62.25%) were infected with different species of clinostomatid metacercariae. The external examination of some infected *O. niloticus* revealed the presence of scattered visible yellow to orange pea like encysted metacercariae on skin and embedded in the musculature with irritated scales (Plate 1, a).

#### **Morphological examination:**

The different types of metacercariae were identified as members of two subfamilies:

- Family Clinostomatidae Lühe 1901 emend Dollfus, 1932.
- (1) Subfamily Clinostomatinae Pralt, 1902.
- Genus *Clinostomum* Leidy, 1856.
- They were differentiated into two species:

#### **1-Metacercariae of *Clinostomum phalacrocoracis*. Dubois 1931:**

The cysts had thin transparent membrane and contained a yellowish fluid. The prevalence rate of infection was 30.75% (Table 4). They were yellow to orange and varied in size from 2.7-5.2 mm. They were detected in pharyngeal region and branchial chamber. The intensity of infection ranged from 5-12 metacercarial cysts per fish. (Plate 1, b & Plate 2, a).

#### **2-Metacercariae of *Clinostomum tilapiae*. Ukoli, 1966**

The encysted metacercariae were detected in both skin and internal organs (branchial cavity, pharyngeal regions and gills) where their prevalence rate of infection was 1.5% and 18.25% respectively (Tables 4, 5). The cysts were visible, yellow to orange pea sized and measured 1.5-3.6 mm. The intensity of infection ranged from 3 to 5 external cysts per skin per fish while it varied from 2-8 internal cysts per infected fish. The cysts which were detected in skin were scattered and embedded in the musculature with irritated scales while those of internal organs were aggregated (grape like) (Plate 1, a, b & plate 2, b).

-(2)Subfamily Euclinostomatinae Yamaguti 1958.

-Genus *Euclinostomum* Travassos, 1928.

#### **a-Metacercariae of *Euclinostomum ardeolae* El-Naffar and Khalifa, 1981.**

These visible encysted metacercariae were embedded in the tissues of the anterior and posterior portions of the kidney of *Oreochromis niloticus*. The cysts are of variable size (2-4 mm) with thin wall but completely tight and exerting pressure on its content so that there is no free space inside the cyst around the larva. They appear as round to oval greyish black cysts and give the area around it faint black colour. The prevalence rate of infection was 12%. The

intensity of infection varies from 1-5 metacercarial cyst per infected fish (Table 5, Plate 1, c & Plate 2, c).

### **b-Metacercariae of *Euclinostomum heterostomum* Rudolphi, 1809:**

Encysted metacercariae were large pea sized and measured 2.8-5.6 mm. The cyst wall was very thick and hide the internal structures. They were spherical in shape, dark yellowish in colour and embedded in the tissues of either anterior or posterior portions of the kidneys. The prevalence of infection was 3.25%, while the intensity varied from 1-3 metacercarial cyst per infected fish (Table 5, Plate 1,c & Plate 2,d).

### **Experimental work:**

Experimental infection of laboratory bred puppies with infected muscles of *O.niloticus* containing microscopic encysted metacercariae resulted in the detection of two mature flukes Viz *Prohemistomum vivax* and *Haplorchis yokogawai*. Faecal examination revealed the appearance of their eggs after 5-7 days post infection (Plate 4, d).

### **Morphological characters of the detected trematodes:**

Two trematodes were isolated and identified as:

#### **1-Family Cyathocytylidae Poch 1926:**

Subfamily Prohemistominae Lutz, 1933.

Genus *Prohemisotomum* Odhner, 1893.

#### ***Prohemisotomum vivax* Sonsino 1893:**

It was recovered from the duodenum, jejunum and ileum of puppies after being fed on the previously described *P. vivax* metacercariae infecting *Oreochromis niloticus*.

### **Morphology:**

The adult trematode is pyriform, convex dorsally and concave ventrally behind the middle half of the body. The total length of the worm is 1.13-1.48 mm while the breadth at the level of the anterior testes is 0.46-0.69 mm. The cuticle of the anterior half of the body is provided with minute spines. The oral sucker is subterminal, rounded, measures 0.05-0.07 mm long by 0.06-0.08 mm wide. The acetabulum is rounded, measures 0.033-0.0446 mm by 0.043 - 0.049 mm. The tribocytic organ is present posterior to the acetabulum. The pharynx is well developed, oval in shape, measures 0.042-0.072 mm long by 0.04-0.08 mm wide. The oesophagus leads to two intestinal caeca ending at a level posterior to the posterior testes. The two large testes are tandem in position with a narrow intertesticular space. The anterior one overlaps the tribocytic organ.

The ovary is small, rounded, lies posterior or posterolateral to the anterior testes and measures 0.10-0.23 mm long by 0.08-0.25 mm wide. The vitellaria are well developed, irregularly shaped of closely packed follicles and forms a complete circle around the tribocytic organ.

The cirrus pouch is saccular shaped and contains the seminal vesicle and rod shaped cirrus (Plate 4, c). The eggs within the uterus are few 1-3 in number (average 2) each is large, oval shaped, yellowish in colour and measure 75 – 90 µm long by 40-65 µm wide (Plate 4, d). The prepatent period is found to be 5-6 days.

#### **2-Family Heterophyidae Odhner, 1914:**

-Subfamily Haplorchinae Looss, 1899.

- Genus *Haplorchis* Looss, 1899.

#### ***Haplorchis yokogawai* Katsuta, 1932:**

The parasite was collected from the ileum of puppies experimentally infected with the microscopic metacercariae found in the muscles

of *O. niloticus*. The adult trematodes were found buried deep in the mucous membrane of the intestine.

**Morphology:**

The adult fluke is oval or pear shaped and extremely small in size measuring 0.530-0.665 mm long by 0.275-0.372 mm wide (0.66×0.28 mm).

The cuticle is provided with spines. The oral sucker measures 0.033-0.046 mm long by 0.035-0.058 mm wide (0.032×0.043). The acetabulum is embedded in the parenchyma. The

prepharynx is short and the pharynx leads to an oesophagus measuring 0.025-0.048 mm (0.036 mm). The single testis is spherical and lies near the posterior extremity measuring 0.089-0.122 mm (0.106 mm). The ovary lies pretesticular, measuring about 0.073×0.065 mm. The uterus which contains numerous eggs extends from behind the bifurcation of intestinal caeca to the posterior end. The vitellaria are follicular, small, few in number and lies at the posterior part of the body in the ovario-testicular zone. No cirrus pouch is observed (Plate 4, e, f).

**Table (1): Prevalence of different species of encysted metacercariae in the body of *O. niloticus***

Examined fish	Infected Fishes											
	Total infection		Single Microscopic meta . inf.		Single Clinosomatid meta . inf.		Mixed infection		Total Microscopic meta. inf.		Total Clinosomatid meta. inf.	
	No.	%	No. infected	%	No. infected	%	No. infected	%	No.	%	No.	%
400	339	84.75	90	22.5	26	6.5	223	55.75	313	78.25	249	62.25

**Table (2): Prevalence of different species of microscopic encysted metacercariae in the body of *O. niloticus***

Examined fish	Infected Fishes									
	<i>Pr. vivax</i>		<i>H. yokogawai</i>		Unidentified cysts		Mixed infection		Total	
	Single infection	%	Single infection	%	No. infected	%	No. infected	%	No. infected	%
400	199	49.75	14	3.5	10	2.5	90	22.5	313	78.25

**Table (3): Prevalence and distribution of microscopic encysted metacercariae per gram of muscle tissue in the different parts of *O. niloticu***

Total examined fish	Total infested	%	Average number of encysted metacercariae per gram tissue		
			Head region	Trunk region	Tail region
400	313	78.25	42-77(65)	65-115(92)	55-98(81)

**Table (4): Prevalence and distribution of clinostomatid metacercariae in the body of *Oreochromis niloticus***

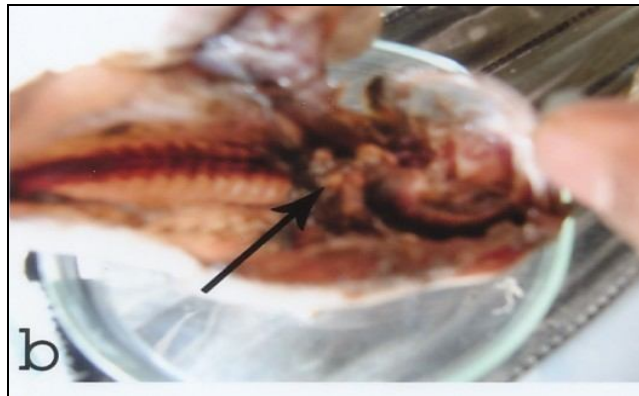
Total examined fish	Total infected fish	%	Distribution of different Clinostomalid metacercariae					
			Branchial chamber, pharyngeal region and gills		Skin		Kidney	
			No	%	No	%	No	%
400	249	62.25	190	47.5	6	1.50	53	13.25

**Table (5): Prevalence and intensity of different species of clinostomatid metacercariae in the body of *O. niloticus***

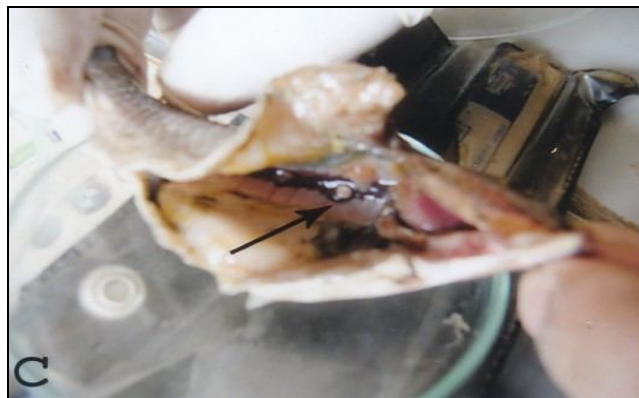Species of encysted metacercariae	Total examined fish	No. of infected fish	%	Intensity per fish
<i>Clinostomum phalacrocorasis</i>	400	123	30.75%	5-12 cyst
<i>Clinostomum tilapiae</i>	400	73	18.25%	2-8 cyst
<i>Euclinostomum ardeola</i>	400	48	12%	1-5 cyst
<i>Euclinostomum heterostomum</i>	400	5	1.25%	1-3 cyst



a) Encysted metacercariae of *Clinostomum tilapiae* in the skin of *O. niloticus*. (arrow).

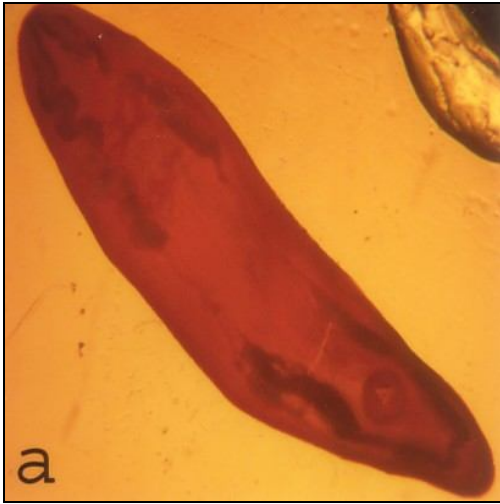


b) Encysted metacercariae of *Clinostomum sp.* in the branchial chamber of *O. niloticus* (arrow)

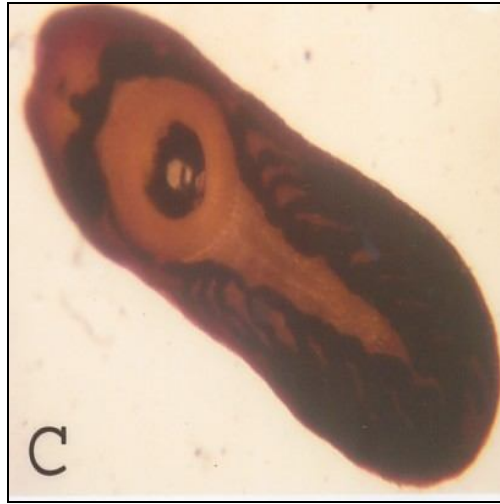

c) Encysted metacercariae of *Euclinostomum ardeolae* in the anterior portion of the kidney of *O. niloticus* (arrow)

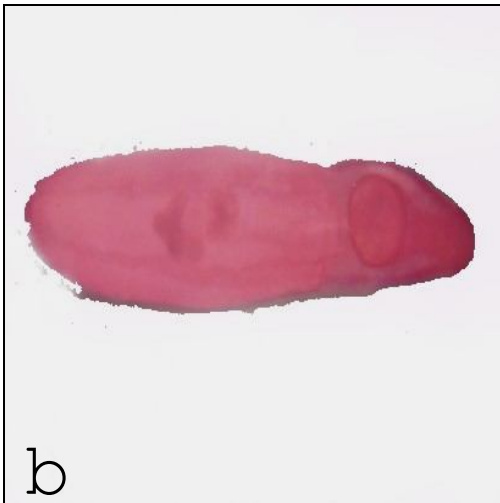
**Plate (I): Clinostomatid encysted metacercariae in the body of *Oreochromis niloticus***



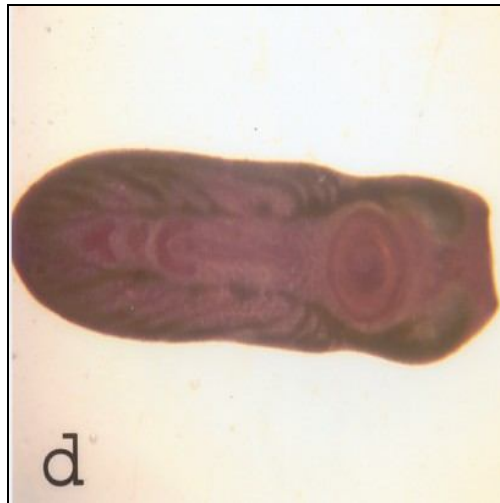
a) Excysted metacercaria of *Cl. phalacrocoracis*



c) Excysted metacercaria of *Euclinostomum ardeolae*



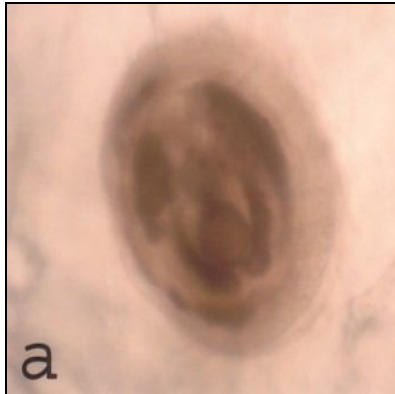
b) Excysted metacercaria of *Cl. tilapiae*.



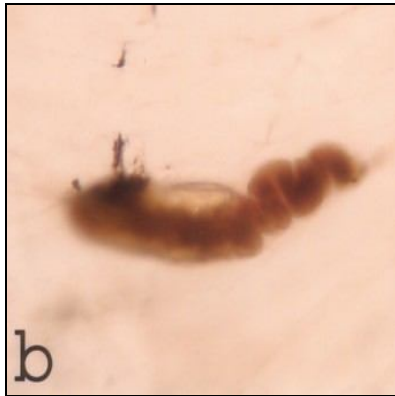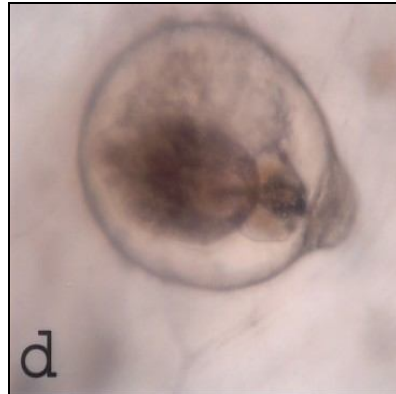d) Excysted metacercaria of *Euclinostomum heterostomum*.

**Plate (2): Clinostomatid excysted metacercariae stained with acetic acid alum carmine**

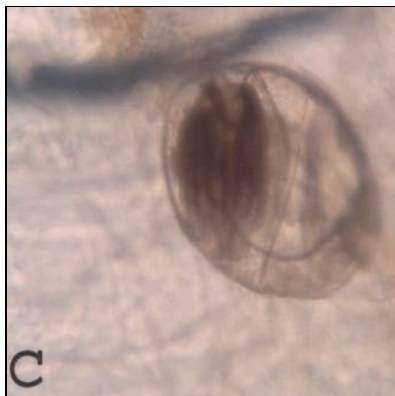
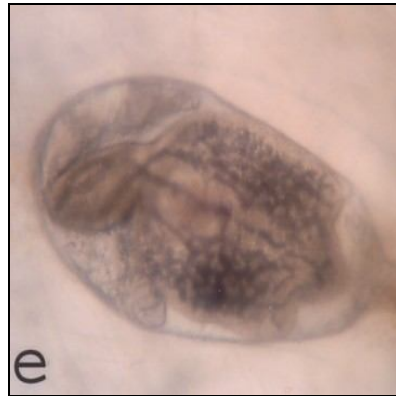


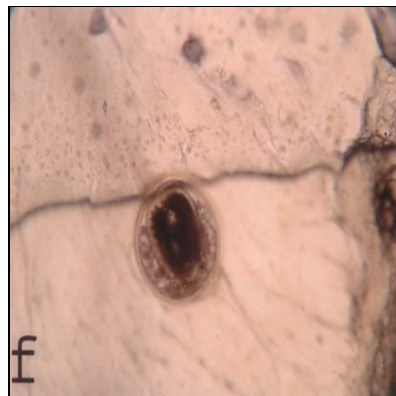
a) Encysted metacercaria of *Prohemistomum vivax* X 100



b) Excysted metacercaria of *P.vivax* X 100

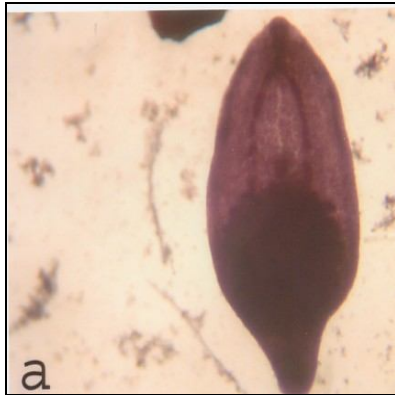


c) Encysted metacercaria of *Haplorichis* sp. X 100.

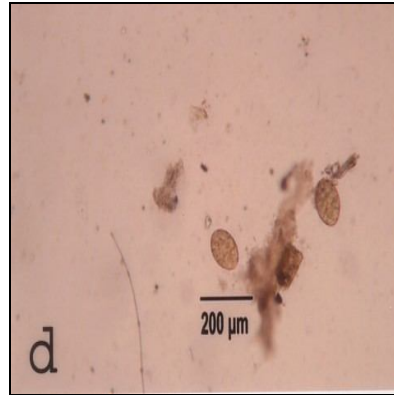


(d, e, f) Unidentified species of microscopic encysted metacercariae in the muscles of *O.niloticus* X 100.

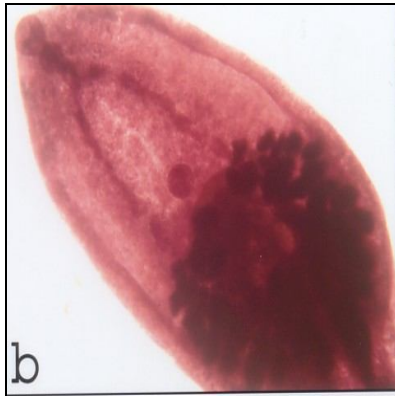
**Plate (3): Microscopic encysted metacercariae in the muscles of *O.niloticus*.**



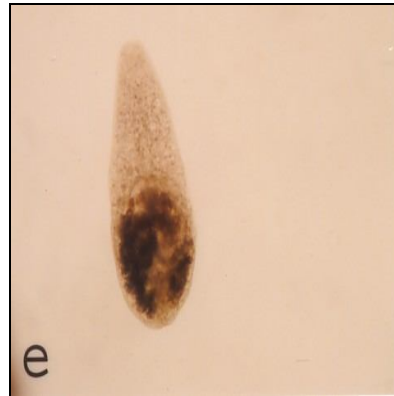a) *Prohemistomum vivax* adult worm X 100.



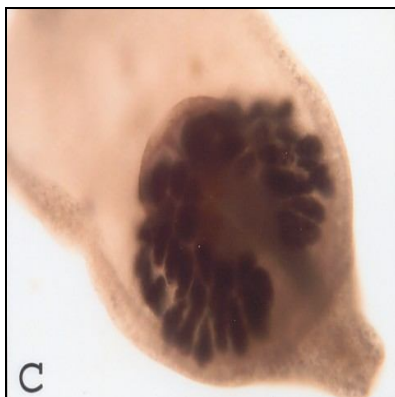d) Egg of *P. vivax* X 100



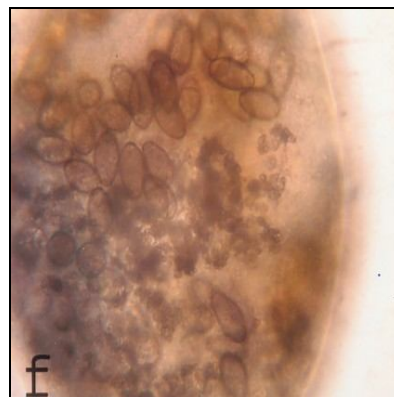b) Anterior part of *P. vivax* adult X 100



e) *Haplorchis yokogawai* adult worm X 100



c) Posterior part of *P. vivax* adult X 100



f) *H. yokogawai* adult worm showing numerous eggs inside the uterus X 400.

**Plate (4) Shows the adult flukes collected from the small intestine of experimentally infected puppies**

## DISCUSSION:

The total prevalence of infected *Oreochromis niloticus* with one or more species of encysted metacercariae was 84.75%, while the prevalence of microscopic encysted metacercariae and clinostomatid metacercariae were 78.25% and 62.25% respectively. These findings are nearly similar to those given by Shalaby (1982) 69.57%, Awad (1992) 68.50% and Hussein (2007) 73.72%. The results were higher than those reported by Shaheen (1998) 29.2%, Arafa *et al.*, (2005) 42.86% and Abd-El-Rahman (2005) 45%, However Khattab (1990) recorded higher prevalence 87.06%. The present study suggests that such variation in incidence may be related to the difference in the habitat, food supply, abundance of both aquatic snails (the intermediate host) and the aquatic piscivorous birds which play the main role to complete the life cycle of some digenetic trematodes. The infection rate with the encysted metacercariae of both *Prohemistomum vivax* and *Haplorchis spp* was 72.25% and 26% respectively. A single host may harbour more than one type of metacercariae. El Shahawi (1983) and Hussein (2007) reported that the rate of infestation with metacercariae of *P. vivax* and *Haplorchis spp.* in *Tilapia nilotica* muscles was 74%, 33% and 73.5%, 19.6% respectively.

Concerning the density of infection with microscopic encysted metacercariae it was found that the highest density with metacercariae in *O. niloticus* was found in the trunk region and the lowest in the head region, such results agreed with the results of Mousa *et al.* (2000) who stated that the metacercariae in *T. nilotica* fish was found mostly in the trunk region followed by the tail and head regions of the fish. On the other hand the present findings disagreed with those given by El-Shahawi (1985) who reported that the highest density of

metacercariae in *T. nilotica* fish was found in the head region and the lowest in the trunk region. The highest density of the microscopic metacercariae (42-115) in different regions of *O. niloticus* in the present investigation may be related to the abundance of Gastropoda near the banks of river and tricklets continuously releasing a huge number of cercariae that attack the integument, subcutaneous tissues, eyes, gills and other organs (Martin & Kuntz 1955). Regarding the distribution of different species of Clinostomatid metacercariae in the body cavity of *O. niloticus*, it was found that the branchial chamber was the most common habitat for them (47.5%) followed by kidneys (13.25%) and skin (1.5%). (Table 4).

These findings may be attributed to the fact that the branchial chamber is adjacent to the gills which are considered the most important part in the fish body rich in blood, persuading the helminth for parasitism. These findings agreed with those reported by Eissa *et al.* (1996) and Arafa *et al.*, (2005).

Identification of clinostomatid metacercariae in the present work was based on the previous description of Yamaguti (1958) and Ukoli (1966). They were identified into *Clinostomum phalacrocorasis*. (30.75%), *Clinostomum tilapiae* (18.25%), *Euclinostomum ardeolae* (12%) *Euclinostomum heterostomum* (1.25%). The parasitological examination during the present work revealed that the clinostomatid encysted metacercariae found in the branchial cavity, pharyngeal regions and gills were the larval stages of digenetic trematodes *Cl. phalacrocorasis* and *Cl. tilapiae*. The prevalence of *Cl. phalacrocorasis* and *Cl. tilapiae* in examined *O. niloticus* was 30.75% and 18.25% while the intensity was 5-12 and 2-8 metacercarial cyst per fish respectively. The present findings agreed with those reported by

Ebraheem (1992) who found *Cl. phalacrocoracis* in *Tilapia spp.* fish with prevalence of 35.17% and the metacercaria burden varied from 2-8 per infected fish. The present results disagree with those recorded by Mohamadin (1989) who reported that the prevalence of *Cl. phalacrocoracis* and *Cl. tilapiae* in *T. nilotica* fish was 5.26% and 34.5% respectively while the intensity was 2-6 and 2-16 metacercarial cyst per fish respectively, Also Abd-El-Rahman (2005) reported that the intensity of encysted metacercariae of *Cl. tilapiae* among the diseased *O. niloticus* fish ranged from 3-65 cysts per fish branchial cavity, while our results are higher than those reported by Mahdy (1991) who recorded that the number of metacercariae ranged from 1-3 per fish in wild *T. nilotica*. *Cl. tilapiae* was detected externally in the skin with a prevalence rate (1.5%), while the intensity ranged from 3-8 cysts per *O. niloticus* skin. These results disagree with those given by Abd-El-Rahman (2005) who reported that the intensity of the encysted metacercariae ranged from 5-50 cysts per *O. niloticus* skin. This difference may be attributed to some different factors such as type of food, water supply, abundance of aquatic snails (intermediate host) and time of examination.

In the course of the present work it was found that the prevalence rate of *Euclinostomum ardeolae* and *Euclinostomum heterostomum* encysted metacercariae detected in the kidneys of *O. niloticus* was 12%, and 1.25% while the intensity was 1-5 and 1-3 metacercarial cysts per fish respectively. These findings was nearly similar with that given by Gado *et al.*, (1999), Abd-El-Rahman (2005) and Arafa *et al.*, (2005), while it was higher than that given by Mahdy (1991) 8.10%, Ebraheem (1992) 1.38% and Eissa *et al.*, (1996) 2.66%, however Tantawy (1997) recorded higher prevalence 44.9% in Abbassa Aquaculture fish ponds.

The description of these detected metacercariae was nearly identical with that given by El-Naffar and Khalifa (1981), El-Shahawi (1983), Yoakim & El-Naffar (1986), Ebraheem (1992) and Arafa *et al.*, (2005). The cysts appear as round to oval brownish black cysts and give the area around faint black colour. Such colouration may be due to the kidney reaction in which melanomacrophages migrate producing melanin pigments (Donges, 1974 and Wolke, 1992).

It was difficult to confirm the identification of the different kinds of microscopic metacercariae when they were encysted in fish or after isolation (Noga, 2000). For this reason the microscopic metacercariae collected from various parts of the fish were pooled and used for experimental infection of laboratory bred puppies. The present experimental work showed that two genera of adult flukes were obtained after 5-7 days post infection, where their eggs start to be detected from experimentally infected puppies. Examination of stained adult worms showed that they are two species Viz *Prohemistomum vivax* and *Haplorchis yokogawai*. The two digenetic trematodes described in the present investigation appears to be very identical with the adult trematodes which had either been found in natural or experimental infection reported by other workers (Azim 1938, Fahmy and Selim 1959, Fahmy *et al.*, 1976, El-Naffar *et al.*, 1985 and Shalaby 1985).

The present study indicates that *Oreochromis niloticus* acts as a second intermediate host for *P. vivax* and *H. yokogawai* while dogs act as a final or definitive host . These results support those investigated by previous workers (Fahmy and Selim 1959, Fahmy *et al.*, 1976 and El-Naffar *et al.*, 1985). The two detected genera of flukes *P. vivax* and

*H. yokogawai* are transmissible to man (Nasr 1941, Watson 1960, Khalifa *et al.*, 1977 and Tadros & El-Mokadem 1983). The susceptibility of man to these parasites increases the medical importance of examination of *Oreochromis niloticus* in Assiut Governorate.

On the other hand the other unidentified microscopic encysted metacercariae investigated in the muscles of *O. niloticus* after feeding to laboratory bred puppies did not develop to adult parasites, this may indicate that dogs are not the final host of these species and the final host is probably a fish eating bird.

#### CONCLUSION:

*Oreochromis niloticus* acts as a second intermediate host for some digenetic trematode parasites including *Cl. phalacrocoracis*, *Cl. tilapiae*, *Euclinostomum ardeolae*, *Euclinostomum heterostomum*, *Prohemistomum vivax* and *Haplorchis yokogawai*. These parasites play an important role in determining the health status of fish and can cause an economic loss and public health problems. Dogs act as a final host of some digenetic trematodes including *P. vivax* and *H. yokogawai* through ingestion of infected muscles of *O. niloticus* fish. The present author could isolate these parasites from experimentally bred puppies. Humans may be susceptible in the same way as dogs through eating raw or insufficiently cooked or partially salted fish. Therefore the present parasites appear to have public health significance. Further investigation should be done in the future on the aquatic birds to identify the adult trematodes of the unidentified encysted metacercariae isolated during the present work.

#### REFERENCES:

- Abd-El-Rahman, A. M. M. (2005): Studies on prevailing parasitic diseases among some fresh water fishes caused by Digenetic trematodes SCVMJ, VIII (1) 13;24.
- Arafa, M.I; Shaheen, M.S. and Monib, M.M. (2005): Studies on some clinostomatid metacercariae from *Tilapia nilotica* in Assiut Governorate. Assiut Vet. Med. J. 51. (107)218-227.
- Awad, A.H. (1992): An approach to the internal parasitic infection in diseased fresh water fishes M. V. Sc. Fac. of Vet. Med. Cairo Univ.
- Azim, M.A. (1938): On the intestinal helminthes of dogs in Egypt, J. Egypt. Med. Ass. 21 (3), 1-5.
- Donges, J. (1974): The life cycle of *Euclinostomum heterostomum* (Trematoda, Clinostomatidae). Internat. J. Parasitol., 4: 79-90.
- Ebraheem, M.E. (1992): Studies on some of the parasites in some Nile fishes in Sohag Governorate. Ph. D. Thesis, Fac. of Sci., Sohag Assiut University.
- Eissa, I.A.M.; Diab, A.S. and Badran, A.F. (1996): Studies on some internal parasitic diseases among wild and cultured *Oreochromis niloticus* fish. 7<sup>th</sup> Sci. Cong. Fac. Vet. Med. Assiut Egypt.
- El-Naffar, M.K. and Khalifa, R.M. (1981): *Euclinostomum ardeolae* Sp. Nov. (Trematoda: Clinostomatidae). J. Egypt. Soc. Parasit., 11(1) 175-181.
- El-Naffar, M.K. and El-Shahawi G.A.Z. (1986): Studies on the metacercariae of the Nile fishes at El-Mini Province, A.R. Egypt. Assiut Vet. Med. J. 15. (30) 46:58.
- El-Naffar, M.K.; Sauod, M.E. and Hassan, I.M. (1983): A general survey of the helminth parasites of some fishes from lake Naser

- of Asswan A.R. Egypt. Assiut Vet. Med. J. 11, (21): 141-148.
- El-Naffar, M.K.; Saoud, M.F. and Hassan, I.M. (1985): Role played by fish in transmitting some trematodes of dogs and cats at Asswan Province, A.E. Egypt. Assiut Vet. Med. J. 14, (27)56:72.
- El-Shahawi, G. A. Z.(1983): Studies on some fishes as intermediate hosts of helminth parasites of some birds and mammals. Master Degree of Science. Fac. of Science, El-Minia Univ.
- Fahmy, M.A.M. and Selim, M.K. (1959): Studies on some trematode parasites of dogs in Egypt with special reference to the role played by fish in their transmission Z. Parasitenkunde, 19: 3-13.
- Fahmy, M.A.; Mandour, A.M. and El-Naffar, M.K. (1976): Successful infection of dogs and cats by *Prohemistomum vivax* Sontano, 1893 and *Haplorchis yokogawai* Katsuta, 1932 J. Egypt. Society Parasit. 6: 77-82.
- Gado, M.S.M. and El-Bahy, N.M. (1999): *Euclinostomum heterostomum* affection of cultured *Oreochromis niloticus* in Kafr El-Sheikh Governorate SCVMJ II (1): 41: 49.
- Hernandez, E.M.; Constantino, C.; Gracia, M. and Osorlo, S.O. (1998): Gill lesions in common carp, *Cyprinus carpio* in Mexico due to the metacercariae of *Centrocestus formosonus*. J. Fish Dis., 21:229-232.
- Hussein, E.A.M. (2007): Role played by fish in transmitting helminth human parasites M. Sc. Thesis, in Parasitology, Fac. Med. Assiut Univ.
- Khalifa, R.; El-Naffar, M.K. and Arafa, M.S. (1977): Studies on heterophid cercariae from Assiut Province. 1-Notes on the life cycle of *Haplorchis pumilio* (Looss, 1896) Trematoda: Heterophyidae) with a discussion on previously described forms. Acta parasitol. Polonica 25, (3): 25: 38.
- Khattab, M.H. (1990): Some studies on Platyhelminthes infesting some freshwater fishes in Egypt M.V.Sc. Thesis, Fac. of Vet. Med., Alex. Univ.
- Kurse, G.O.W. and Pritchard, M.H. (1982): The collection and preservation of animal parasites. Nebraska Univ. Press. USA.
- Mahdy, O.A. (1991): Morpho-biological studies on the role of some fresh water fishes in transmitting parasitic helminthes of some avian hosts. Ph. D. Thesis, Fac. of Vet. Med. Cairo Univ.
- Mahdy, O.A.; Eissa, M.A. and El-Easa, M. (1995): Parasitological and pathological studies on heterophid infection in *Tilapia* sp. From Manzala, Egypt. J. Comp. Pathol. Clin. Path., 8: 131-145.
- Mahmoud, N.A. (1983): Parasitic infestation of some native species fishes in Cairo markets with special reference to man and animals. M. V. Sc. Thesis, Cairo Univ.
- Martin, W.E. and Kuntz, R.E. (1955): Some Egyptian Heterophyid trematodes. J. Parasit., 41(4): 374-382.
- Mohamadain, H.S. (1989): Studies on helminth parasites of Nile fishes in Quena Province. M. Sc. Thesis Fac. of Sci., Quena, Assiut Univ.
- Mousa, W. M.; Mahdy, O. A. and Kandil, O.M. (2000): Electrophoretic analysis to confirm the identification of some kinds of encysted metacercariae from *Oreochromis niloticus* Assiut, Vet. Med. J. 43 (85) 199:209.
- Nasr, M. (1941): The occurrence of *Prohemistomum vivax* infection in man, with redescription of the parasite. Lab. and Med. Prog., 2: 135-149.

- Noga, E.N. (2000): Fish diseases (diagnosis and treatment) Blackwell Science Ltd., U.S.A. 378PP.
- Paperna, I. (1991): Parasites, infections and diseases of fish in Africa. CIFA committee for inland fisheries of Africa.
- Shaheen, M. S. I. (1998): Morphological studies on metacercariae of *Clinostomum species*. Egypt. J. Med. Sci. 19 (2) 339-352.
- Shalaby, A.S. (1982): Studies on the enteric helminth parasites of fishes from lake Manzala. M. V. Sc. Thesis, Fac. Vet. Med., Cairo Univ.
- Shalaby, S.I. (1985): Further studies on the role played by catfish in transmitting some trematodes to fish eating mammals with special reference to the morphology of *Mesostephanus appendiculatus* Ph. D. Thesis, Fac. Vet. Med. Cairo, University.
- Srisawangwong, T.; Pinlaor, S; Kanala, P. and Sithithaworn, P. (1997): *Centrocestus formosanus* surface morphology of metacercariae, adult and egg J. Helminthol., 71:345:350.
- Svobodova, Z. and Kolarova, J. (2004): A review of the diseases and contaminant related mortalities of tench (*Tinca tinca* L.) Vet. Med. Czech, 49(1): 19: 34.
- Tadros, G. and El. Mokaddem, E.E.A. (1983): Observations on heterophyids affecting man in Egypt. Bull. Zool. Soc. Egypt, 33: 107-111.
- Tantawy, E. A. (1997): Safety and quality of fishes infested with parasites Ph. D. Thesis, Fac. Vet. Med, Cairo Univ.
- UKoli, F. M. A. (1966): On *Clinostomum tilapiae* n. sp. and *Clinostomum phalacrocrasis* from Ghana and a discussion of the systemics of the genus *Clinostomum* J. Helminthol., 40: 417-423.
- Watson, J.M. (1960): Medical Helminthology. Bailliere Tindall Cox. London 487 PP.
- Williams, H.H. and Jones, A. (1976): Marine helminthes and human health. Commonu. Inst. Helminthol. Misc. Publ. 3, 47.
- Wolke, R.E. (1992): Piscine macrophage aggregates. Ann. Rev. Fish. Dis., 2: 91: 108.
- Yamaguti, S. (1958): *Systema Helminthum*, Vol. I. Digenetic Trematodes, Part I and II. Inter Science Publishers Inc., New York. 1575, PP. 106pl.
- Yoakim, E.G. and El-Naffar, M.K. (1986): Studies on the effects of metacercariae of the parasitic trematode *Euclinostomum ardeolae* on the kidneys of the Nile cichlid fish *Tilapia nilotica* J. Assiut Vet. Med., Journal, 15 (30):30:37.

بعض الدراسات على الميتاسركاريا المتحوصلة فى أسماك البلطى فى محافظة أسيوط والدور الذى تلعبه تلك الأسماك فى نقل بعض الديدان الورقية للكلاب

جمال أمين طاهر

معهد بحوث صحة الحيوان بأسيوط

أجريت هذه الدراسة على عدد 400 سمكة من أسماك البلطى النيلى ذات أحجام مختلفة فى محافظة أسيوط وذلك للتعرف على الأنواع المختلفة للأطوار اليرقية المتحوصلة لديدان التريماتودا. بلغت نسبة الإصابة الكلية بالأطوار اليرقية المتحوصلة 84.75% حيث تم تصنيفها إلى نوعين هما الحويصلات المجهرية وحويصلات الكلينوستوماتيد. بلغت نسبة الإصابة بالحويصلات المجهرية 78.25% وكانت منتشرة فى عضلات الذئع والذيل والرأس بينما بلغت نسبة الإصابة بحويصلات الكلينوستوماتيد 62.25%، وكان التجويف الخيشومى أكثر الأماكن تعرضاً للإصابة (47.5%) ثم تليه منطقة الكلى 13.25% بينما بلغت نسبة الإصابة فى الجلد 1.5% تم تصنيف ميتاسركاريا الكلينوستوماتيد فى أسماك البلطى النيلى إلى أربعة أنواع، وهى كلينوستومم فالاكروكوراسز، كلينوستومم تيلابيا، إيوكليينوستومم أرديولا وإيوكليينوستومم هيتيروسومم وكذلك تم التعرف على نوعين من الميتاسركاريا المجهرية وهى ميتاسركاريا فيفاكس وميتاسركاريا من نوع هابلوركس من النسيج العضلى لمنطقة الذئع والذيل والرأس. تم تحديد نسبة إصابة كل نوع من الحويصلات المختلفة وتسجيل كثافة وجودها فى أعضاء الجسم المختلفة. وقد أجريت دراسة تجريبية لمعرفة أنواع الميتاسركاريا المجهرية المختلفة، وذلك بعدوى الكلاب الصغيرة الخالية من الطفيليات معملياً بإطعامها لحوم أسماك البلطى النيلى المصابة، وتم التعرف على نوعين مختلفين من الديدان البالغة، والتي تنتمى لعائلة الديدان الورقية هما: بروهيمستومم فيفاكس، هابلوركس يوكا جاواى عُرِلت هذه الديدان من الغشاء المخاطى المبطن لأمعاء الكلاب بعد 5-7 أيام من العدوى التجريبية.